



MATRAC

Mountain Area Trauma Regional Advisory Committee

Trauma Guideline Manual

Prepared by the Trauma Surgery Service
Trauma Center Mission Hospitals
Asheville, NC

December 2000

Revisions:

2002, 2003, 2005, 2007, 2009

MATRAC MEMBER HOSPITALS

Angel Medical Center, Franklin
Cannon Memorial Hospital, Linville
Cherokee Tribal Hospital, Cherokee
Harris Regional Hospital (Westcare Health System), Sylva
Haywood Regional Medical Center, Clyde
Highland-Cashiers Hospital, Highlands
Mission Hospitals, Asheville
Murphy Medical Center, Murphy
Margaret R. Pardee Memorial Hospital, Hendersonville
Park Ridge Hospital, Fletcher
Rutherford Hospital, Rutherfordton
Saint Luke's Hospital, Columbus
Spruce Pine Community Hospital, Spruce Pine
Swain County Hospital (Westcare Health System), Bryson City
The McDowell Hospital, Marion
Thom's Rehabilitation Hospital, Asheville
Transylvania Community Hospital, Brevard
Veterans Affairs Medical Center, Asheville

MATRAC MEMBER EMS SYSTEMS

Avery County EMS, Newland
Buncombe County Emergency Services, Asheville
Burke County Emergency Services, Morganton
Cherokee County Emergency Services, Murphy
Cherokee Tribal Emergency Medical Services, Cherokee
Clay County Emergency Medical Services, Hayesville
Graham County Emergency Services, Robbinsville
Haywood County Emergency Medical Services,
Waynesville Henderson County Emergency Medical Services, Hendersonville
Macon County Emergency Medical Services, Franklin
Madison Emergency Medical Services, Marshall
McDowell County Emergency Services, Marion
Mitchell Emergency Medical Services, Ledger
Polk County Emergency Medical Services, Columbus
Rutherford County Emergency Medical Services, Rutherfordton
Swain County Emergency Medical Services, Bryson City
Transylvania County Emergency Medical Services, Brevard
Westcare Emergency Medical Services, Sylva
Yancey Emergency Medical Services, Burnsville

Table of Contents

INTRODUCTION.	Page 1
Definition of the Trauma Patient.	Page 2
Trauma Team Response.	Page 3
Resuscitation Role Assignments.	Page 3
Operating Room Notification.	Page 7
Universal Precautions.	Page 7
Radiologic Evaluation.	Page 8
Resuscitation Priorities.	Page 9
Airway Management.	Page 12
Cricothyrotomy.	Page 13
Blunt Chest Injuries.	Page 14
Widened Mediastinum.	Page 20
Blunt Cardiac Injury.	Page 21
Penetrating Chest Injury.	Page 23
Insertion of Chest Tube.	Page 24
Pericardiocentesis.	Page 26
Emergency Resuscitative Thoracotomy.	Page 27
Peripheral and Central Intravenous Access.	Page 28
Blood and Blood Product Transfusion.	Page 30
Anticoagulant/Antiplatelet Reversal.	Page 31
Massive Transfusion Protocol.	Page 33
Prevention of Hypothermia.	Page 33
Trauma Arrest.	Page 34

Traumatic Brain Injury.....	Page 36
Neck Immobilization.....	Page 38
Cervical Spine Clearance.....	Page 39
Tetraplegia or Paraplegia.....	Page 41
Thoracic and Lumbosacral Spine Injuries.....	Page 44
Blunt Abdominal Trauma.....	Page 45
Blunt Abdominal Trauma (For Non-ultrasound Credentialed Resuscitation).....	Page 46
Focused Abdominal Ultrasound.....	Page 47
Diagnostic Peritoneal Lavage.....	Page 49
Penetrating Abdominal Trauma.....	Page 50
Splenic Injuries.....	Page 52
Liver Injuries.....	Page 53
Damage Control.....	Page 56
Intra-abdominal Hypertension.....	Page 57
Pelvic Fractures.....	Page 58
Open Fracture.....	Page 59
Penetrating Neck Injury.....	Page 61
Pediatric Patient.....	Page 62
Traumatic Incidents During Pregnancy.....	Page 64
Management and Triage of Severely Burned.....	Page 65
Deep Venous Thrombosis Prophylaxis.....	Page 68

INTRODUCTION

In medicine, few situations can be so demanding as the initial management of the multiply injured patient. The successful outcome of the resuscitation will be determined by the level of skills of the resuscitating team, the speed and teamwork with which the resuscitation is carried out, and the precision of the diagnosis and treatment utilized.

This manual was written to accomplish the following goals:

1. To standardize the delivery of trauma care to the victims of major trauma in Western North Carolina.
2. To aid in the appropriate utilization of resources.
3. To help in the orientation of new health care providers to the MATRAC Trauma System protocols, procedures and operations.
4. To optimize resuscitation teamwork throughout the MATRAC region
5. To help reduce transfer delays and EMTALA concerns by outlining clearly the accepted transfer policy of trauma victims from the region to the Trauma Center at Mission Hospitals.

Trauma remains the third leading cause of death in this country, truly a "neglected disease". Trauma kills more people under the age of 40 years than any other cause of death and is the leading killer of children. This terrible toll in human lives, family suffering, and loss of productivity is intolerable and unacceptable. Only the sophisticated definitive care capability of Emergency Medicine and surgical personnel coupled with an efficient pre-hospital system will permanently reduce trauma morbidity and mortality. This concept has been will proven in military combat experience. Battlefield mortality has been drastically reduced in recent conflicts through the utilization of well-trained pre-hospital providers and rapid patient evacuation to a facility equipped and staffed to meet the needs of the trauma victim. That such a system is equally efficacious in the civilian setting has also been well documented.

The Mountain Area Regional Trauma Advisory Committee is dedicated to this concept of rapid, aggressive and appropriate therapeutic intervention in the major trauma victim. Commitment of all members of the trauma community in the region is the most essential component of any trauma care system. MATRAC hopes to exemplify that commitment.

NOTE: The guidelines in this manual are strictly "suggestions" and educational tools for the management of the trauma patient and the performance of procedures. In no way are they intended to be limited approaches to the problems presented to the Trauma Team. Obviously, many interpretations of these guidelines can be made which are quite appropriate to trauma care in individual circumstances. The approach to each patient should be individualized to fit the particular needs of the patient and the available resources of the Trauma Team. The key tenet of state of the art trauma care remains providing the expertise and resources necessary to maximize recovery potential. At times this will be accomplished locally and at times this will necessitate timely transfer to the Trauma Center.

Additional, evidence based trauma care guidelines may be accessed at: www.east.org Check under Practice Guidelines heading.

PRACTICE GUIDELINES: Definition of the Trauma Patient and Movement Through the Trauma System

OBJECTIVE:

1. To provide a uniform definition of the type of patient for which the Trauma System will be activated.

GUIDELINES:

1. Mission Hospitals in Asheville, NC has made the commitment to Western North Carolina to be the resource Trauma Center in Western North Carolina. Mission currently meets or exceeds all state criteria for a Level II Trauma Center. The Trauma Service is available to treat and admit any seriously injured patient at high risk of dying or suffering morbidity from multiple and severe injuries. In general, the definitions proposed by the Committee on Trauma of the American College of Surgeons will be utilized. It is the policy of the Trauma Service at Mission to accept in transfer any patient a regional provider would benefit from trauma center care.
2. The majority of trauma patients can, and should, receive definitive care at the nearest Regional Hospital. A small percentage, 5-8% will require transfer to the Trauma Center. The triage decision is the responsibility of the Emergency Department attending at each facility. It is incumbent upon that physician to be familiar with the degree of definitive care capability at his/her facility. If the patient's need exceed that capability, then prompt movement through the Trauma System is in the best interest of the patient. This may involve: air medical directly to the scene, ground EMS by-pass of the nearest facility directly to the Trauma Center, air medical or ground transport from Regional Facility to the Trauma Center.
3. Consider Immediate Trauma Center Diversion/Transfer
 - a. Compromised airway.
 - b. Systolic BP < 90 mmHg in an adult or signs of shock in a pediatric patient.
 - c. Head injury with depressed or deteriorating GCS, lateralizing signs, penetrating injury.
 - d. Major chest wall injury with respiratory compromise.
 - e. Unstable pelvic fractures.
 - f. Amputation proximal to wrist or ankle.
 - g. Major vascular injury.
 - h. Intubated trauma patients.
 - i. Limb paralysis.
 - j. Penetrating injuries to torso, head, neck or extremity with pulse deficit.
 - k. Multiple system injury with compromise.
4. Consider prompt Trauma Center transfer
 - a. Two or more proximal long bone fractures.
 - b. Widened mediastinum.
 - c. Anticipated prolonged mechanical ventilatory support.
 - d. Pelvic fractures.
 - e. Pregnancy >24 weeks with suspected abdominal or pelvic injury.
 - f. Flail chest.
 - g. Medically compromised trauma victims.
 - h. Age < 5 years or > 55 years.

- i. Other patients at the discretion of the Emergency Department attending.

NOTE: All such decisions rest with the Emergency Medicine physician in Regional Hospitals. It is vital to remember and understand that major trauma victims must move through the Trauma System quickly to realize maximum benefit from the system. Complete, definitive, time consuming radiologic evaluation is neither necessary nor desirable prior to Trauma Center transfer. This is the standard of care established by MATRAC in 2000 and has not changed.

The Emergency Medicine physician at Mission is authorized to accept any trauma patient in transfer from the region. This decision will be supported by the on-call Trauma Surgeon. It is necessary for the referring MD to speak only with the EM MD at Mission to initiate the transfer.

PRACTICE GUIDELINES: TRAUMA TEAM RESPONSE

THE TRAUMA TEAM

The definition and composition of the Trauma Team will vary from facility to facility depending on resources.

The victim of major trauma faces a deadly foe, i.e., time. Trauma patients do not have time for a leisurely "wait your turn" diagnostic process, for evaluation by late arriving specialists, or for lethargic resuscitation. The longer the time interval from injury to appropriate definitive care, the higher the morbidity and mortality. To reduce the time factor as a contributor to morbidity and mortality, the Trauma Team must exist and function.

At Mission Hospital Trauma Center, the Trauma Team is lead by the Trauma Surgeon, who is Board Certified in General Surgery and Surgical Critical Care. The remainder of the team is multidisciplinary consisting of Emergency Medicine, nursing, radiology, laboratory, respiratory therapy, security, and clergy. The pre-hospital providers are considered an intimate component of the Trauma Team and their information from the scene and technical assistance is invaluable.

The composition of the Trauma Team and the functions of its members will vary from hospital to hospital in the based on resources available. The aggressive approach to evaluation and resuscitation should not vary.

PRACTICE GUIDELINES: RESUSCITATION ROLE ASSIGNMENTS

OBJECTIVES:

1. To define the roles of the members of the Trauma Team during a trauma resuscitation.
2. To provide optimal patient care by defining specific responsibilities for each member of the Trauma Team.

The following is offered as a template to be modified by regional Emergency Medicine, Emergency Nursing and General Surgery to provide optimum local resource utilization and patient care. Roles and responsibilities will vary depending on whether the patient is being prepared for transfer to the Trauma Center or to receive definitive care locally.

GUIDELINES:

1. For a resuscitation to be efficient, every member of the team should understand his/her particular responsibilities. These should be organized into tasks to be completed before the patient arrives, and during the initial assessment and resuscitation of the trauma victim. When a patient with multi-system trauma arrives requiring several procedures to

be done simultaneously, the assignment of roles as outlined below should be strictly followed to prevent chaos.

Team Leader

The Team Leader should be designated prior to the arrival of the patient and is usually the Emergency Medicine attending or Trauma Surgeon. If the Team Leader is required to leave the bedside then the responsibility should be transferred to another qualified senior team member.

The Team Leader will direct the course of the Primary Survey and resuscitation and expect a response to his or her questions; all questions or information should be directed to this person. There should be no other extraneous conversation.

1. Prior to patient arrival:
 - a. Assembles the trauma team and makes specific role assignments.
 - b. The most senior surgeon calls anesthesia and OR personally if the patient is to go straight to the OR.
 - c. Confirms that everyone in the unit has gown, mask, cap, eye protection, and gloves.
 - d. Reviews information from ambulance radio report.
2. Primary assessment and resuscitation:
 - a. Receives verbal report directly from ambulance personnel.
 - b. Performs the Primary Survey.
 - c. Makes the decision for airway control.
 - d. Decides on IV orders and additional venous assess.
 - e. Determines the amount and type of blood (O-negative, type specific, etc.) needed.
 - f. Categorizes the injuries.
 - g. Orders initial X-rays, determines order of priority, orders labs.
 - h. Determines whether and when Trauma Center transfer is to occur.
3. Secondary assessment and definitive care:
 - a. Performs the Secondary Survey.
 - b. Examines X-rays.
 - c. Decides on the need for and priority of further X-rays.
 - d. Contacts consultants as needed.
 - e. Decides promptly on transfer, continued work up or provision of definitive care.
 - f. Talks with family.
 - g. Completes appropriate documentation.

Primary RN

1. Generally remains at the patient's right side
2. Directs/supervises all non-physician personnel.
3. Monitors vital signs (BP, P, RR, pulse oximetry, ongoing neuro signs, etc.).
 - a. Initial BP measurement obtained manually.
4. May insert right-sided IV's.
5. Communicates with/reassures patient.
6. Communicates assessments and interventions to the Leader.

7. Accepts medical orders from the Leader.
8. Administers medications at the direction of the Leader.
9. May insert naso/oro-gastric tube, Foley, etc.
10. Delegates duties to nursing and ancillary personnel as appropriate.
11. Monitors effects of medications and treatments and communicates patient response to Leader.
12. Anticipates and sets up equipment and procedure trays.
13. Sets up blood warming equipment and administers blood.
14. Communicates problems, needs, and current status to ED charge nurse.
15. Responsible for proper completion of the Trauma Flow Sheet.

Respiratory therapist

1. Assists "airway physician" at the head of bed.
2. Assures suction, ETCO₂ detectors and all intubation equipment available and ready.
3. Performs manual bag ventilation.
4. Monitors patient respiratory status.
5. Provides ventilatory set-ups.
6. Coordinates ventilator set-ups for other areas where patient is to move.
7. Communicates assessments and interventions to the Leader.

Radiology technician

1. Performs portable X-rays as directed by Leader.

Scribe

1. Documents assessments, tests, and interventions on the Trauma Flow Sheet.

Chaplain (or social worker)

1. Assists with identifying patient.
2. Contacts patient's family.
3. Keeps appropriate family members informed of patient's status.
4. Facilitates psychosocial care of patient, family and visitors.
5. Coordinates family visits to the bedside with the Leader and Primary Nurse.
6. Supports the grieving process.
7. Assist with patient/family interviews regarding violence, abuse, etc.

Team members are strategically placed around the stretcher based on their tasks. They are coordinated with equipment placement within the resuscitation bay (figure taken from Resources for Optimal Care of the Injured Patient)

Airway Control/MD (may be surgeon, anesthesiologist/anesthetist, or emergency physician) or RN

- Establishes clear airway
- Intubates
- Performs or assists with procedure

Registered Nurse

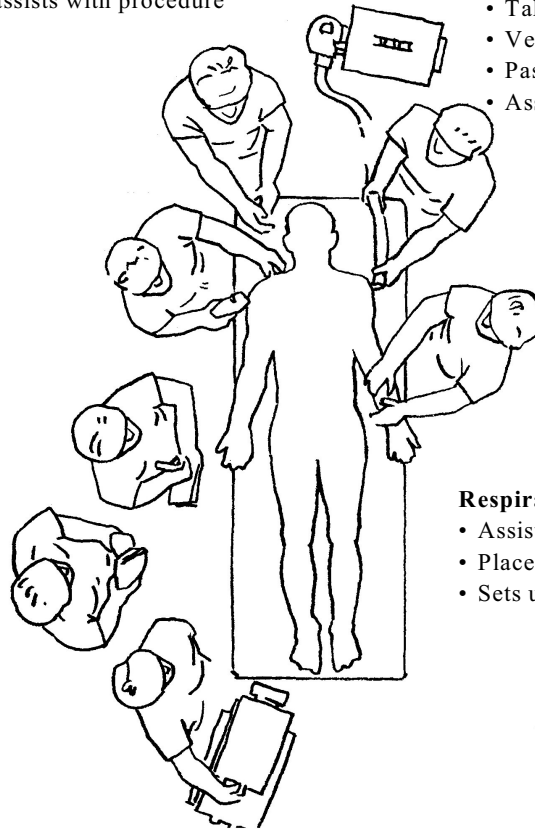
- Takes vital signs
- Venous access/blood drawing
- Passes equipment
- Assists with procedures

Trauma Surgeon/Team Leader

- Initial assessment and survey
- Coordinates all team activities
- Performs or assists with procedure

Registered Nurse/Primary Nurse

- Calls alert
- Prepares area
- Records vital information
- Assists with procedures



Respiratory Therapist

- Assists with airway control
- Places monitoring devices
- Sets up ventilator

Blood Bank or Laboratory

- Brings blood from the blood bank
- Carries samples to laboratory

Radiographer

- Films as needed

PRACTICE GUIDELINES: Operating Room Notification

OBJECTIVE:

1. To define a mechanism to notify the operating room of the need to transfer a patient for an immediate surgical procedure.

GUIDELINES:

1. Follow ATLS Guidelines for initial resuscitation.
2. When the need for emergent or urgent operative intervention is determined, contact the operating room. The most senior surgical physician on the team will be responsible for making this call.
3. Convey the following information:
 - a. Patient name and hospital number.
 - b. Attending surgeon.
 - c. Type of procedure to be performed (e.g., laparotomy, thoracotomy, neck exploration, etc.)
 - d. The need for the cell-saver (yes or no).
 - e. The approximate time that the procedure should be performed (yesterday, now, 5 minutes, 15 minutes, etc.).
 - f. Any other important information (special equipment, cell-saver, X-ray, etc.).
 - g. "Warm the room." 80 – 85°.
4. The surgeon should also speak with anesthesia providing notification of the case with the following information:
 - a. All of the above information.
 - b. IV line locations.
 - c. Hemodynamic stability.
 - d. How much fluid and blood has been given.
 - e. Anticipated findings at surgery.
 - f. Any special anesthesia equipment or procedure needed (e.g., pulmonary artery catheter, A-line, TEE, double lumen endotracheal tube, etc.) If the surgeon would like to keep the patient intubated after the case, this would be a good time to discuss it with anesthesia.
5. Once the need for emergent operation has been made, proceed as quickly as possible to the operating room.

PRACTICE GUIDELINES: Universal Precautions

OBJECTIVE:

1. To define the minimum standards for universal precautions and the situations in which they are to be applied.

GUIDELINES:

1. Universal precautions consist of barrier protection of the health care provider to prevent transmission of infections from the patient's bodily fluids.
2. All Patients Are Assumed to Have Blood and Bodily Fluid Infections That Are Transmissible. Additionally, Trauma Patients Are Immunosuppressed and Require

Protection.

3. Universal precautions consist of:
 - a. Impervious gown covering the exposed clothing and arms of the health care provider.
 - b. Gloves.
 - c. Eye protection.
 - d. Booties to cover footwear.
 - e. Surgical masks.
 - f. All members of the trauma team that will be in contact with the patient or the exposed bodily fluids will utilize universal precautions.

PRACTICE GUIDELINES: Radiologic Evaluation of Trauma Patients

OBJECTIVE:

1. To provide guidelines for the proper ordering of X-rays on multiple trauma patients.

GUIDELINES:

1. Usual order of resuscitation room X-rays.
2. Supine chest X-ray.
 - a. In general, almost all multiply injured patients require a supine chest X-ray. (The evaluation of the trauma patient has slowly evolved over the last 10 - 15 years. In patients who are stable and the ER physician has determined that the patient will require a CT scan of the torso, a CXR might not add value to the patient's workup and therefore can be omitted.)
 - i. On all patients with suggestion of chest injury.
 - ii. Obtain as soon as possible in intubated patients.
3. AP pelvis. (Again, in patients who the ER physician has determined that the patient will need a CT scan of the torso, an AP pelvis film can be omitted.)
 - a. Obtain on all obtunded patients with a possible mechanism suggesting a pelvic injury expect in patients who are going to undergo a CT scan of the abdomen and pelvis.
 - b. If the patient is alert and cooperative, obtain portable pelvis X-ray when there are signs and symptoms of pelvic injury.
 - c. A pelvis film does not need to be ordered on every patient.
4. C-spine (cross table lateral):
 - a. Many trauma centers have almost completely stopped taking plain films of the neck in multiply injured patients. These patient have a high likelihood of requiring CT scans of the head, chest, abdomen or pelvis. A CT scan of the cervical spine is quicker than obtaining plain films and the diagnostic accuracy for detecting injuries is much higher.
 - b. The cervical spine cannot be "cleared" for manipulation based solely on the results of a lateral cervical spine film. This film is optional as a resuscitation room X-ray since even "normal" results of this film do not allow manipulation of the spine.
5. Other resuscitation films should be obtained only if the information from them is urgently needed (e.g., foreign body identification in GSW, etc.) or if the patient too unstable to proceed from the resuscitation room.
6. Retrograde cystogram:

- a. Should be considered for cases of gross hematuria, penetrating abdominal trauma and pelvic fractures where bladder disruption is suspected. Allow 300 ml of contrast agent to flow into Foley catheter and then clamp. X-ray with the bladder full and then repeat the X-ray after drainage of the contrast.
7. Retrograde urethrogram:
 - a. Should be considered for all cases of gross hematuria where disruption of the urethra is suspected.
 - i. Blood at the urethral meatus.
 - ii. High riding prostate.
 - iii. Obvious perineal injury (perineal hematoma or open perineal injury or scrotal hematoma).
 - b. Insert small (12 Fr.) Foley catheter into the meatus for a distance of 2-3 cm. Inject 10-20 cc gently.
 - c. X-ray tube should be centered over pubic tubercle.
 - d. If Foley catheter has been previously placed, may be performed alongside the catheter by inserting 18 gauge angiocath next to Foley.
8. CT Scans.
 - a. Obtain as indicated. **Do not delay** transfer for CT scan if results of CT will not effect decision to transfer.
 - b. In trauma patients, CT scans to evaluate abdominal trauma **must** always include the pelvis and must always (in the absence of contraindications) be done with iv contrast. CT scans for abdominal trauma without contrast can miss significant injuries and delay diagnosis/treatment.
 - c. Oral contrast is generally not necessary.

PRACTICE GUIDELINES: Resuscitation Priorities for the Multiply or Seriously Injured Patient

OBJECTIVE:

1. The following protocol outlines the priorities for managing the seriously injured patient according to ATLS guidelines, currently published guidelines such as those from the Society of Critical Care Medicine, the American Association of Neurological Surgeons and the Eastern Association of Trauma. Detailed review of those evidenced based guidelines and updates can be viewed on the web sites of those societies: www.sccm.org, www.aans.org and www.east.org. This is a framework for the ongoing resuscitation, although it must be recognized that deviations will be necessary according to the patient's status and ongoing re-evaluation. **It must be remembered, definitive and time consuming patient evaluation prior to transfer to the Trauma Center is *not necessary* and frequently not beneficial to the trauma victim. The following sequence can and should be interrupted at any time it is clear the patient will require transfer to the Trauma Center.**

GUIDELINES: (The protocol below lists the priorities in the primary survey, resuscitation, and secondary survey phases of trauma management as adapted from ATLS.)

1. Primary Survey
 - a. Airway: guarantee patency and assure that the patient can (or not) protect his/her airway.

See Practice Guideline: Airway Management and Endotracheal Intubation.

- i. Assume C-spine injury in blunt trauma – maintain in-line stabilization (rigid collar and lateral immobilization):
 - (1) 100% oxygen
 - (2) Suction secretions using Yankauer suction. Remove foreign bodies. Jaw thrust if necessary to open the airway.
 - (3) Oral or nasopharyngeal airway if tolerated by patient.
 - (4) If necessary, orotracheal intubation with RSI and with in-line stabilization.
 - ii. Brain injury – rapid sequence intubation when Glasgow Coma Scale is 8 or less.
 - iii. Apneic – immediate orotracheal intubation with in-line stabilization or surgical cricothyrotomy.
- b. Breathing: See Practice Guideline: Management of Blunt Chest Trauma.
- i. Assess breath sounds bilaterally.
 - ii. Mechanical ventilation if ventilatory effort is inadequate.
 - (1) Bag-Valve-Mask initially.
 - (2) Verify ET tube position by auscultation in axilla, over the epigastrium **and** end tidal CO₂ determination.
 - (3) Ventilatory support with Ambu bag or ventilator.
 - iii. Tension pneumothorax:
 - (1) Immediate needle thoracostomy (14 or 16 gauge IV catheter in second intercostal space along the midclavicular line) followed by tube thoracostomy.
 - iv. Hemothorax:
 - (1) Thoracostomy tube after fluid resuscitation.
 - (2) Plan for autotransfusion if available
 - v. Simple pneumothorax:
 - (1) Tube thoracostomy depending on size and patient status after confirmation by chest X-ray.
 - vi. Open pneumothorax:
 - (1) Cover defect with Vaseline dressing.
 - (2) Place Tube thoracostomy.
 - (3) Surgical closure of chest wall defect.
- c. Circulation:
- i. Hemostasis – direct pressure to bleeding wounds.
 - ii. Reverse anticoagulants or antiplatelet medications ASAP. See Practice Guideline: Anticoagulation/Antiplatelet Reversal.
 - iii. Treat shock.
 - iv. Assess for etiology.
 - (1) **Hypovolemic Shock** most common cause of shock in trauma. External blood loss. Intrathoracic hemorrhage. Intraabdominal hemorrhage. Retroperitoneal hemorrhage. Hemorrhage from long bone fractures and/or pelvic fracture are among the most common causes of hypovolemic shock.
 - (2) **Neurogenic Shock** considered if evidence of spinal cord injury, hypotension, bradycardia, warm, pink skin.
 - (3) **Obstructive Shock** consider tension pneumothorax, pericardial tamponade.

- (4) Other forms of shock are rarely seen in acute trauma patients - Cardiogenic shock, Septic shock
- v. Treatment
 - (1) Warm crystalloid solution, initially 2 liters LR/NS, then packed cells through a fluid warmer.
 - (2) Early operative/angiographic control of hemorrhage vs protracted volume loading.
 - (3) In Brain or lung injury – maintain adequate fluid resuscitation to keep BP and pulse in normal range. Strive to maintain normal hemodynamics and euvolemia.
 - (4) Cardiac tamponade: pericardiocentesis, needle or open (especially with anterior chest penetrating injury).
 - (a) Shock with reduced pulse pressure transiently responsive to volume.
 - (b) Neck vein distention or elevated CVP.
 - (c) Rule out tension pneumothorax, since this is more likely than tamponade in blunt trauma.
- d. Disability. Central nervous system injury. (See Practice Guideline: Management of Traumatic Brain Injury).
 - i. Assess Glasgow Coma Scale (for GCS < 8, intubate with RSI).
 - ii. Continue resuscitation to maintain euvolemia.
 - iii. Maintain oxygenation >95%.
 - iv. "Mild" hyperventilation to achieve pCO₂ around 35 mmHg – not lower.
 - v. Medications:
 - (1) Sedate with morphine/fentanyl and/or short acting benzodiazepine to avoid agitation and protect airway.
 - (2) In consultation with Neurosurgery, consider Mannitol 1 gm/kg in deteriorating. Do not use in hemodynamically unstable patients.
 - (3) If seizures are present - Ativan 1 –2 mg IV doses
 - (4) Cerebyx (fosphenytoin) 20 mg/kg IV no faster than 150 mg/min or Dilantin (phenytoin) 20 mg/kg to be given over 20 minutes if indicated for prophylaxis against further seizures.
 - vi. CT scan of head, as indicated.
- e. Expose/Examine/Environment
 - i. Remove all clothing. Examine the patient looking for long bone fractures and other injuries. Now may be the best opportunity to log roll the patient and examine the back.
 - ii. Maintain normothermia. See Practice Guideline: Prevention of Hypothermia.
 - (1) Warm blankets.
 - (2) Overhead heating lights.
 - (3) Warm IV fluids.
 - (4) Keep resuscitation room very warm (80-85°).
 - (5) Baer Hugger
 - iii. Insert naso/oro-gastric tube and Foley catheter, as indicated.

- f. Conduct Secondary Survey
 - i. Head-to-toe physical examination
 - ii. Need for Trauma Center transfer should have been established in Primary Survey and arrangements well underway at this point.
 - iii. Continued reassessment is ABSOLUTELY mandatory.
 - iv. Vital signs: frequent determinations of vital signs, as determined by the severity of injury, should be made.
 - v. Outputs: should be checked frequently during the resuscitation phase and then hourly when stable – urine, chest tube, naso/oro-gastric.
 - vi. Remain alert to trends in physical examination and vital signs in response to interventions.
 - vii. Continue to re-evaluate.

PRACTICE GUIDELINES: Airway Management and Endotracheal Intubation

OBJECTIVES:

1. To define the indications for the need for airway control.
2. To provide a procedure guideline for the insertion of an endotracheal tube for the purpose of airway protection and to provide access for positive airway pressure ventilation.

GUIDELINES:

1. Indications:
 - a. Impairment of level of consciousness (GCS < 8).
 - b. Chest injury with respiratory insufficiency.
 - c. Respiratory failure.
 - d. Facial trauma with present or impending airway compromise.
 - e. Facial burns and smoke inhalation.
 - f. Protection of the airway in the absence of gag reflex.
 - g. Impending airway obstruction from any cause.
2. Preparation and equipment:
 - a. Universal precautions.
 - b. ET tube: Largest size appropriate to the patient. The cuff should be tested. The stylet may be inserted but should not extend beyond the hole in the end of the tube (Murphy's eye).
 - c. Syringe: a 10 ml syringe should be attached to the tube.
 - d. Laryngoscope: this should be tested before use.
 - e. Ambu-bag with oxygen supply and ETCO₂ detector.
 - f. IV access.
 - g. Induction drugs at bedside (analgesic, sedative, neuromuscular blocker, lidocaine for brain injuries, atropine for children).
 - h. Monitors – both EKG and pulse oximeter.
 - i. Assume C-spine injury exists and maintain C-spine immobilization.
 - j. Suction equipment at hand and working.
 - k. Equipment for "Plan B" immediately available, e.g., surgical airway, Combitube, LMA, etc.
3. Technique:

- a. A few minutes pre-oxygenation should precede intubation whenever possible.
 - b. Muscle relaxants: the use of muscle relaxants renders the patient apneic and unable to protect the airway from aspiration of pharyngeal contents. With rapid sequence intubation, cricoid pressure must always be applied and not released until tube placement is confirmed. In addition, muscle relaxants make sequential neurologic evaluation impossible. Therefore, they should be used following a screening neurologic exam consisting of gross motor, sensory, level of consciousness and pupillary exams.
4. Procedure
- a. Secure all equipment as listed above
 - b. Pre-oxygenate with 100% O₂
 - c. Administer lidocaine 1mg/kg in presence of brain injury
 - d. Administer sedation, e.g., Versed, Etomidate and analgesic, e.g., fentanyl, morphine as condition dictate
 - e. Cricoid pressure throughout procedure
 - f. Administer succinylcholine 1mg/kg IVP*
 - g. Intubate, check and confirm proper tube position, secure tube
 - h. Administer vecuronium 0.1mg/kg IVP after confirming tube position
 - i. Re-administer sedative and give narcotic each 30 minutes while patient pharmacologically relaxed. Neuromuscularly blocked patients are still awake and able to feel pain.

*The choice of neuromuscular blocker, analgesic and sedative is determined by the local EMS protocol and MD preference. Drugs and dosages are listed in the tables below.

Sedative and Induction Agents for RSI

Medication	Dosage	Time of Onset	Duration of Action
Etomidate	0.3 mg/kg	60 sec	3 - 5 minutes
Fentanyl	2 - 10 mcg/kg	60 sec	30 - 60 minutes
Midazolam	0.1 - 0.3 mg/kg	2 minutes	1 - 2 hours
Morphine	0.1 mg/kg	2 - 5 minutes	2 - 3 hours

Neuromuscular Blocking Agents

Medication	Dosage	Time of Onset	Duration of Action
Succinylcholine	1 - 2 mg/kg	30 - 60 seconds	4 - 6 minutes
Rocuronium	0.6 - 1.2 mg/kg	2 minutes	30 minutes
Vecuronium	0.15 - 0.25 mg/kg	3 - 5 minutes	30 - 40 minutes

PRACTICE GUIDELINES: Cricothyrotomy

GUIDELINES:

1. Indications:
 - a. An inability to get an emergent airway after an adequate attempt at endotracheal intubation.
 - b. An initial approach to the airway in patients with:
 - i. Severe facial trauma with distortion of the face and nose.
 - ii. Upper airway obstruction.
2. Equipment:
 - a. No. 6 Shiley tracheostomy tube (or smaller for younger patients) or a No. 6 endotracheal tube.
 - b. Betadine, lidocaine, syringe, needle.
 - c. Instruments:
 - i. #15 or 11 scalpel.
 - ii. Hemostat.
 - iii. Sponges
 - iv. Tracheal spreader
3. Procedure:
 - a. Place the patient in the supine position if possible. Due to impending airway obstruction from secretion management, this procedure may have to be done in the decubitus position.
 - b. Prep neck with Betadine. Use local anesthesia if the situation permits.
 - c. Stabilize the thyroid cartilage.
 - d. Make a transverse or longitudinal incision over the cricothyroid membrane.
 - e. Incise through membrane, being careful not to disrupt the thyroid cartilage or cricoid cartilage.
 - f. Insert hemostat or your index finger through cricothyroid opening to dilate the opening to an appropriate size. As an alternative, insert the tracheal spreader and dilate. Without removing the spreader, insert the tube through spreader into the trachea.
 - g. Insert either a tracheostomy tube or endotracheal tube into the cricothyroid opening. Make sure that the tube is not advanced past the carina.
 - h. Inflate cuff and ventilate patient with bag-valve-mask.
 - i. Confirm intratracheal position with in usual fashion.
 - j. A cricothyroid tube hangs precariously from the patient's neck. Probably the most important part of this procedure is securing the tube so it does not get dislodged. Losing this airway could be disastrous as injured tissues bleed and collapse the newly created cricothyrotomy. Secure the endotracheal tube or tracheostomy tube with trach ties.
 - k. Observe chest movement and auscultate chest to determine adequate air insufflation.

PRACTICE GUIDELINES: Management of Blunt Chest Injuries

GUIDELINES:

1. Blunt chest injuries are characterized by:
 - a. Mechanism:
 - i. Severe blunt force applied to the chest. Rapid deceleration injury.
 - b. Signs:

- i. Chest wall deformity
- ii. Paradoxical chest wall motion
- iii. Chest wall contusion
- iv. Deep chest wall laceration
- v. Subcutaneous emphysema
- vi. Distressed breathing pattern
- vii. Hypotension
- viii. Distended neck veins
- ix. Absent or diminished breath sounds
- c. Symptoms:
 - i. Tachypnea
 - ii. dyspnea
 - iii. "I think I am going to die"
 - iv. Pain
 - v. Hemoptysis

With any of the above findings, consider the possibility of the following chest injuries: Tension pneumothorax, open pneumothorax, flail chest, pulmonary contusion, massive hemothorax, cardiac tamponade, blunt cardiac injury, ruptured diaphragm, ruptured tracheobronchial tree, ruptured thoracic aorta, ruptured esophagus, myocardial tear, simple pneumothorax, fractured ribs

- 1. Maintain airway:
 - a. Intubate as patient condition warrants.
 - b. Beware of worsening pneumothorax as positive pressure is applied to the airway.
 - c. If time allows, obtain portable AP chest X-ray:
 - i. Evaluate for possible chest injury. Confirm tube placement.
 - ii. In general, all transfers who have had a chest X-ray at another facility should have a repeat chest X-ray after arrival.
 - iii. Chest tubes should be placed prior to the chest X-ray if there is hemodynamic compromise.
 - iv. For severe anterior chest trauma, obtain an emergent EKG and observe monitor for bundle branch block or dysrhythmias or cardiac injury pattern.
- 2. Treat injury according to the diagnostic findings:
 - a. Tension pneumothorax:
 - i. Physiology: air enters the pleural space and cannot exit:
 - (1) Respiratory compromise due to increased pleural pressure.
 - (2) Hemodynamic compromise due to impaired venous return.
 - (3) Contralateral lung is affected by mediastinal shift.
 - ii. Diagnosis:
 - (1) Respiratory distress.
 - (2) Absent unilateral breath sounds.

- (3) Asymmetric chest wall motion.
 - (4) Hypotension with distended neck veins.
 - (5) Shift of the trachea.
 - iii. Treatment:
 - (1) Needle thoracostomy followed by large bore chest tube (36-40Fr).
 - (2) Obtain chest X-ray after chest tube has been placed.
- b. Open pneumothorax:
 - i. Physiology:
 - (1) Open defect in chest wall allows air to enter the pleural space
 - (2) Mediastinum shifts as pressure gradients change across the midline.
 - ii. Diagnosis:
 - (1) "sucking chest wound."
 - iii. Treatment:
 - (1) Intubate the patient and place on positive pressure ventilation if patient is in severe distress.
 - (2) Insert large bore chest tube.
 - (3) Cover the defect.
 - (4) Surgical closure of the defect.
- c. Flail chest/Pulmonary contusion
 - i. Physiology:
 - (1) Blunt force to the chest.
 - (2) Ribs fractured in multiple places lead to unstable segment of chest wall.
 - (3) Pain.
 - (4) Pulmonary contusion in underlying area of lung with alveolar hemorrhage and edema resulting in focal compliance reduction and interference with gas exchange.
 - ii. Diagnosis:
 - (1) Paradoxical chest wall movement.
 - (2) Severe pain with breathing or with palpation in the affected area.
 - (3) Respiratory distress.
 - (4) Hemoptysis.
 - (5) Chest X-ray demonstrates contusion.
 - iii. Treatment:
 - (1) Flail chest:
 - (a) Pain control: epidural, PCA, morphine drip.
 - (b) Pulmonary toilet, monitor vital capacity.
 - (c) Intubate for worsening compliance and respiratory distress due to the underlying contusion or increasing pCO₂. Remember to intubate these patients early in their course. Intubating late increases the work of breathing and the patient's cardiac oxygen consumption. In the elderly this can lead to myocardial infarction.
 - (2) Pulmonary contusion:
 - (a) Pulmonary toilet, monitor vital capacity.

- (b) Intubate for worsening compliance, respiratory distress or hypoxemia.
 - (c) Maintain normovolemia. Previously many experts suggested that these patients should be kept dry. Renal dysfunction was frequently seen when keeping patients dry so this is no longer the recommendation.
- d. Massive hemothorax:
 - i. Physiology:
 - (1) Massive bleeding into the pleural space results in hemorrhagic shock.
 - (2) After blunt trauma, source is usually bleeding from the chest wall.
 - ii. Diagnosis:
 - (1) Hemorrhagic shock and hemothorax on chest X-ray.
 - (2) Absent breath sounds on affected side.
 - (3) Dull to percussion on affected side.
 - iii. Treatment:
 - (1) Fluid resuscitation to correct hemorrhagic shock.
 - (2) Place large bore chest tube after attaching autotransfusion device to pleural collection device.
 - (3) If initial drainage >1200 ml or drainage continues at >200 ml/hr for more than two hours, then consider operative intervention. Operative indications vary between surgeons and the operative threshold in blunt trauma is generally higher than penetrating trauma.
 - (4) If drainage is high, may consider intubation and application of PEEP (10-20 cmH₂O) to tamponade chest wall bleeding. Beware of air embolus.
- e. Cardiac tamponade:
 - i. Physiology:
 - (1) Laceration in the atrium, ventricle, or intrapericardial vena cava results in blood loss into the pericardial sac.
 - (2) As blood accumulates in pericardial sac, end-diastolic volume is reduced, resulting in a fall of the cardiac output.
 - (3) Diagnosis:
 - (a) Hypotension and distended neck veins without a tension pneumothorax.
 - (b) Distant heart sounds.
 - (c) "Blue facies."
 - (4) Treatment:
 - (a) IV fluid bolus.
 - (b) Pericardiocentesis
 - (c) If positive, immediately go to OR for median sternotomy or thoracotomy.
- f. Blunt cardiac injury: Refer to Trauma Practice Guidelines www.east.org "Practice Management Guidelines for Screening of Blunt Cardiac Injury"
 - i. Physiology:
 - (1) Contusion of the myocardium results in conduction defects.
 - (2) Contusion may result in reduced contractility.
 - ii. Diagnosis:

- (1) History of severe anterior chest trauma and abnormality in EKG.
 - (2) Unexplained tachycardia.
 - (3) Right bundle branch block.
 - (4) Unexplained nonspecific ST-T wave changes.
 - (5) New Q-waves.
 - (6) New arrhythmia (atrial fib/flutter, PVC's, multifocal PAC's).
 - (7) Unexplained myocardial pump failure (rule out valve injury).
- iii. Treatment:
- (1) With high suspicion, obtain echocardiogram.
 - (2) Monitor telemetry for 24 hours in the hospital - does not have to be in ICU if no other injury warrants it.
 - (3) Treat arrhythmias according to ACLS guidelines.
 - (4) Treat cardiac dysfunction with inotropes.
- g. Ruptured diaphragm:
- i. Physiology:
 - (1) Tear in diaphragm allows abdominal contents to enter the chest, resulting in respiratory distress. The process is more rapid with spontaneous ventilation. Diagnosis may be very difficult and requires a high index of suspicion.
 - ii. Diagnosis:
 - (1) Left:
 - (a) Chest X-ray may reveal abdominal viscera in the chest.
 - (b) Naso/orogastric tube may appear high in the left chest.
 - (c) If necessary, obtain barium swallow to document the location of the stomach or barium enema for location of colon. Confirm with CT, laparotomy, laparoscopy or thoracoscopy
 - (2) Right:
 - (a) An abnormal "hump" in the lateral diaphragm suggests laceration and protrusion of the liver.
 - (b) Confirm with CT, laparotomy, laparoscopy or thoracoscopy.
 - iii. Treatment:
 - (1) Consider early intubation to prevent further migration of abdominal viscera into chest.
 - (2) Operative repair through the abdomen.
 - (3) If diagnosis is delayed, may need a thoracotomy.
- h. Ruptured tracheobronchial tree:
- i. Physiology:
 - (1) massive air leak into the pleural space after tear of the bronchial tree, usually near a point of fixation.
 - ii. Diagnosis:
 - (1) Massive pneumothorax and/or subcutaneous emphysema.
 - (2) Continued massive air leak after placement of the chest tube.
 - (3) Bronchoscopic diagnosis of tear.
 - iii. Treatment:
 - (1) Avoid high ventilating pressures.

- (2) Selective intubation of the uninjured lung using double lumen endotracheal tube if possible.
 - (3) To the operating room for thoracotomy and operative closure.
 - i. Ruptured thoracic aorta:
 - i. Physiology:
 - (1) Aorta ruptures at point of fixation after severe deceleration events. The point of rupture is usually just distal to the left subclavian artery or in the ascending arch.
 - (2) Resulting hematoma is contained by adventitia or pleura.
 - (3) 85% are dead at the scene.
 - ii. Diagnosis:
 - (1) History of severe deceleration impact.
 - (2) Widened mediastinum (see Practice Guideline for Evaluation of the Widened Mediastinum). Also refer to www.east.org Guidelines for the Diagnosis and Management of Blunt Aortic Injury
 - iii. Treatment:
 - (1) Keep blood pressure and heart rate controlled (< 120 mmHg) using analgesia, beta-blocker and vasodilator.
 - (2) Consult Cardiothoracic Surgery and prepare operating room.
 - (3) It should be noted that the treatment of traumatic aortic injuries is in flux. Many vascular and cardiac surgeons are now treating these injuries with endovascular stents after a period of stabilization (1 - 7 days depending on other injuries and co-morbidities).
 - j. Ruptured esophagus:
 - i. Physiology:
 - (1) thoracoabdominal crush injury
 - (2) thoracic vertebral fracture dislocations or penetrating trauma.
 - ii. Diagnosis:
 - (1) Air in the mediastinum.
 - (2) Sputum or intestinal contents out of the chest tube.
 - (3) Confirm with esophagoscopy and/or Gastrografin swallow.
 - iii. Treatment:
 - (1) thoracotomy and repair.
 - (2) early diagnosis is critically important to a successful repair.
 - k. Simple pneumothorax:
 - i. Physiology:
 - (1) Puncture of the lung with air leak into the pleural space. The air in the space is not under excessive pressure.
 - ii. Diagnosis:
 - (1) Absent or decreased breath sounds. Subcutaneous emphysema.
 - (2) Pneumothorax on chest X-ray (supine CXR may miss a significant pneumothorax).
 - (3) Chest pain.

- (4) Occult pneumothorax seen on CT scan without plain film findings can be treated without chest tube. If patient goes to operating room, is intubated or is transferred by air ambulance, then a chest tube probably should be placed.
- iii. Treatment:
 - (1) Chest tube.
- 1. Fractured ribs:
 - i. Physiology:
 - (1) ribs fracture from direct force or chest wall compression.
 - ii. Diagnosis:
 - (1) Chest wall pain.
 - (2) Bony crepitus.
 - (3) Fractured ribs on chest X-ray or CT scan.
 - iii. Treatment:
 - (1) Pain control. This is very important. Without adequate pain control patients will not take deep breaths and progressive atelectasis will lead to respiratory failure. Epidural, PCA (patient controlled analgesia), morphine drip, intercostal blocks and oral narcotics are the mainstays of treatment.
 - (2) Intubation is required in some cases in order to get adequate pain control.
 - (3) Pulmonary toilet.
 - (4) Drain intrapleural fluid accumulation.

PRACTICE GUIDELINES: Evaluation of the Widened Mediastinum

Refer to Trauma Practice Guidelines www.east.org "Guidelines for the Diagnosis and management of Blunt Aortic Injury".

OBJECTIVES:

1. To define the indications of pursuing an evaluation to rule out a thoracic aortic injury. To suggest possible diagnostic paradigms for the evaluation of thoracic aortic injury.

DEFINITIONS:

1. Thoracic aortic injury:
 - a. A disruption of the thoracic aorta from blunt deceleration trauma. This injury is usually at the ductus arteriosum just distal to the take-off of the left subclavian artery. Occasionally, the aorta may rupture in the ascending portion and at the take-off of the major vessels.
2. Widened mediastinum:
 - a. A mediastinum measurement of 8 cm at the level of the aortic knob on the best upright chest film that can be obtained.

GUIDELINES:

1. Initially assume that there is an aortic injury on every patient with a rapid deceleration mechanism of injury.
2. Evaluate and treat the ABC's. Obtain blood pressure in both arms. Assess for symptomatic upper extremity BP differences (> 10 mmHg), pseudocoarctation syndrome or infrascapular

murmur. These are suggestive of aortic injury.

3. Obtain a chest X-ray. The following are chest X-ray findings that are associated with blunt aortic injury. If a widened mediastinum is found and the patient can safely sit up, obtain an upright chest X-ray.
 - a. Examine for a widened mediastinum (8 cm at level of aortic knob). The following signs are suggestive of a possible aortic injury, but in themselves, do not mandate the need for further evaluation. (If the patient is stable, then a CT of the chest can be diagnostic.)
 - b. Pleural cap.
 - c. Depressed left mainstem bronchus.
 - d. Trachea or esophagus deviated to right.
 - e. First and/or second rib fracture.
 - f. Obliterated aorto-pulmonary window.
 - g. Multiple rib fractures.
 - h. Scapular fracture.
4. If the possibility of aortic injury is considered at any point in the resuscitation, avoid hypertension. High blood pressures (> 120 mmHg) should be treated with a short acting intravenous beta-blocker (e.g., labetalol or esmolol).
5. If the mediastinum is still widened or an upright film cannot be performed and the index of concern regarding aortic injury is low, obtain a chest CT scan with cuts through the aortic arch. An alternative is to obtain a transesophageal echocardiogram. If the mediastinum is widened and the index of concern for aortic injury is high, proceed directly to angiography or transfer the patient to a higher level of care.
 - a. If the CT scan shows no periaortic mediastinal blood and the aorta looks normal, then an aortic injury has been ruled out.
 - b. If the TEE shows no evidence of aortic disruption, then an aortic injury has been ruled out.
6. A thoracic angiogram should be obtained in the following circumstance:
 - a. The chest X-ray shows a widened mediastinum and the index of concern for aortic disruption is high.
 - b. A chest CT scan shows blood in the mediastinum or an aortic disruption. The need for angiogram will be determined by the cardiothoracic surgeon.
 - c. A TEE shows aortic disruption or is equivocal or non-diagnostic. If the TEE shows aortic disruption, contact cardiothoracic surgery, since frequently the repair will be performed solely on the basis of the TEE.
 - d. There is a marked disparity between the pulses of the right and left arm.
 - e. There is marked disparity between the pulses of the arms and the legs with no other explanation.

NOTE: If aortic disruption is considered, the patient should be immediately transferred to the Trauma Center for further radiologic investigation where operative intervention can be urgently initiated if needed.

PRACTICE GUIDELINES: BLUNT CARDIAC INJURY

Refer to www.east.org "Practice Management Guidelines for Screening of Blunt Cardiac Injury"

OBJECTIVES:

1. Define the basis of the clinical diagnosis of blunt cardiac injury.
2. Define appropriate laboratory studies to diagnose blunt cardiac injury.
3. Provide guidelines for appropriate treatment of potential blunt cardiac injury.

DEFINITION:

1. Blunt cardiac injury: A bruise of the myocardial muscle that may result in temporary arrhythmias or decrease in or loss of contractile function.

GUIDELINES:

1. Consider the possibility of blunt cardiac injury in the following situations:
 - a. Severe decelerating blunt chest trauma.
 - b. Multiple anterior rib fractures.
 - c. Severe anterior chest pain suggesting rib fractures or chondral fractures.
 - d. Fractured sternum.
 - e. Seatbelt contusion across the anterior chest.
 - f. Severe bilateral pulmonary contusions.
2. Follow the ABC's and treat all chest injuries according to the diagnostic findings.
3. Obtain chest X-ray looking for any of the above radiologic findings.
4. Obtain EKG. Consider EKG abnormal with the following findings:
 - a. Unexplained tachycardia (rate >120).
 - b. New onset ventricular arrhythmias – PVC's, bigeminy.
 - c. New onset atrial arrhythmia - multifocal PAC's, new atrial fibrillation or flutter.
 - d. New onset right bundle branch block.
 - e. New onset Q-waves.
 - f. New onset ST-T wave abnormality.
 - g. Changes compatible with acute MI or conduction deficit.
 - h. Admit patients with abnormal EKG to telemetry bed for 24 hours of monitoring.
 - i. Obtain repeat EKG after 24 hours.
5. Consider transthoracic (or, if available, transesophageal) echocardiogram for the following:
 - a. Unexplained hypotension suggestive of cardiac failure.
 - b. Abnormal EKG at 24 hours.
 - c. Persistent arrhythmias.
6. Patient with blunt cardiac injury may safely undergo anesthesia if properly monitored.
7. CPK (CK) isoenzymes and circulating cardiac troponin levels are not useful for predicting which patients have or will have complications related to blunt cardiac injury. CPK (CK) will be elevated in all patients with blunt trauma. Therefore, isoenzymes or troponins are required to aid the with the diagnosis of blunt cardiac injury.
8. If patient has persistent myocardial dysfunction:
 - a. Obtain cardiology consult.
 - b. Treat arrhythmias according to ACLS guideline.
 - c. Treat any cardiac failure with inotropes and consider concurrent placement of a pulmonary artery catheter.

PRACTICE GUIDELINES: Penetrating Chest Injury

OBJECTIVES:

1. To define guidelines for the management of penetrating injuries to the chest.
2. To define an optimal diagnostic strategy and appropriate treatment plans for suspected injuries.

DEFINITION:

1. Penetrating injury to the chest:
 - a. A penetrating injury of the thorax in an area bounded superiorly by the lower neck and inferiorly by the lower costal margin. See also: Thoracoabdominal injuries under "Practice Guideline: Penetrating Injuries to the Abdomen."

GUIDELINES:

1. Any penetrating injury to the chest must be assumed to have caused internal organ damage which may involve the:
 - a. Heart.
 - b. Lungs.
 - c. Tracheobronchial tree.
 - d. Esophagus.
 - e. Great vessels.
 - f. Diaphragm.
 - g. Spinal cord.
2. Assess the ABC's and obtain an airway as quickly as possible.
 - a. If patient has suffered cardiac arrest but has recently (within the last 15 minutes) had signs of life or is in extremis with low blood pressure, proceed directly to left anterior thoracotomy while the patient is being intubated and large bore intravenous lines are being inserted. See "Practice Guideline: Emergency Resuscitative Thoracotomy."
 - b. Determine whether the patient is hemodynamically stable (normal) or unstable (hypotensive or tachycardic) and whether the patient has respiratory distress.
 - i. If hemodynamically unstable or has respiratory distress consider:
 - (1) Tension pneumothorax:
 - (a) Absent breath sounds.
 - (b) Distended neck veins.
 - (c) Shift of the trachea.
 - (d) Insert large bore chest tube (consider needle thoracostomy to temporize).
 - (2) Massive hemothorax:
 - (a) Absent breath sounds on affected side.
 - (b) Dull to percussion on affected side.
 - (c) Stabilize blood pressure with vigorous fluid resuscitation.
 - (d) Insert large bore chest tube with autotransfusion device attached to pleural collection device.

- (i) Take immediately to OR if
 - 1) Initial drainage is >1200 ml, or
 - 2) Drainage continues at >200 ml/hr for 2-3 hours, or
 - 3) Per the discretion of the Trauma or Thoracic Surgeon
- (3) Cardiac tamponade:
 - (a) Entry wound in the cardiac box below the nipples, medial to the mid-clavicular line and above the costal margins
 - (b) Any penetrating wound of the chest or upper abdomen places the heart at risk.
 - (c) Distended neck veins.
 - (d) Distant heart sounds.
 - (e) “Blue facies.”
 - (f) Tension pneumothorax has been treated or ruled out.
 - (g) Perform needle pericardiocentesis.
 - (i) If positive, go immediately to the OR for thoracotomy or median sternotomy.
 - (ii) If patient is stable and has little respiratory distress, obtain AP supine chest X-ray (mark the entry and exit sites with radio-opaque markers).
 - (iii) If X-ray shows:
 - 1) Pneumothorax: place large bore (36 Fr.) chest tube.
 - 2) Hemothorax: resuscitate the blood volume and place large bore chest tube. Be prepared for autotransfusion.
- ii. If the wound is below the nipples, this is considered a thoracoabdominal wound. Refer to Practice Guideline: Penetrating Abdominal Injury. The heart remains at risk from this type wound and should not be overlooked.
- iii. If the injury is in Zone 1 of the neck, consider angiogram, bronchoscopy and esophagoscopy. Refer to Practice Guideline: Penetrating Neck Injury.
- iv. If the injury is between the nipples and between the clavicle and lower costal margin, consider the possibility of cardiac injury with occult cardiac tamponade: Insert CVP to determine central pressure – if it is elevated, consider cardiac tamponade.
 - (1) Perform FAST ultrasound examination or obtain echocardiogram to look for pericardial effusion.
 - (2) If all X-rays are normal and there is no firm indication that the pleural space or mediastinum was penetrated, observe for 6 hours and obtain a repeat inspiratory and expiratory chest X-ray.
 - (3) If there is a pneumothorax or hemothorax, follow guidelines as above. If the film is normal, consider discharge from the ED.

PRACTICE GUIDELINES: Insertion of Chest Tube

OBJECTIVES:

1. To outline the indications for the insertion of a chest tube.
2. To provide a procedure guideline for the insertion of a chest tube (tube thoracostomy) in the trauma patient.

GUIDELINES:

1. Indications:
 - a. Pneumothorax.
 - b. Hemothorax.
 - c. Subcutaneous emphysema of the chest wall in a patient who has sustained blunt chest wall trauma requiring ventilator support or general anesthesia.
 - d. Severe blunt chest wall trauma with multiple fractured ribs requiring ventilator support or general anesthesia in which there is a risk for development of pneumothorax.
2. Equipment:
 - a. A chest tube insertion tray.
 - b. A chest drainage system underwater seal.
 - c. Chest tubes, at least a 32 French.
 - d. Skin preparation solutions and gauze.
 - e. Number 1 or 0 silk or nylon on a medium curved cutting needle.
 - f. Attach autotransfusion collection unit to the chest drainage system with hemothorax.
3. Procedure:
 - a. A basilar chest tube is placed for a traumatic hemopneumothorax. It should be inserted with the patient lying in the supine. A size 32 Fr. or larger tube should be used. **Do not use a trocar.** The objective is for the tube to lie in the paravertebral gutter posteriorly just above the diaphragm. The skin incision should be made horizontally over the fifth or sixth intercostal space in the midaxillary line and the subcutaneous tract should be directly posteriorly, cephalad and medially so that the tube enters the chest through the same intercostal space which the skin incision overlies, only more posteriorly. Alternatively, the skin incision may be placed on intercostal space below the point of entry into the cavity (which is at the 5th or 6th intercostal space).
 - b. The steps for inserting the tube are basically the same regardless of if you are trying to place the chest tube apically or just above the diaphragm. The procedure is:
 - i. Shave and prepare the skin over a wide area of the chest wall.
 - ii. Drape the area with four towels or sterile barriers.
 - iii. You should use universal precautions.
 - iv. Infiltrate the skin with a local anesthetic.
 - v. Make a 2.5 - 3 cm long skin incision well into the subcutaneous tissue. Bluntly dissect down to the ribs with a hemostat or kelly clamp.
 - vi. Infiltrate the pleura with local. This is where most of the pain fibers are. Additionally, some experts suggest to block the intercostal nerves with 2-5 ml of anesthetic medially and laterally to the incision.
 - vii. Continue developing this tract all the way in to the pleura. Remove the scissors or clamp and explore the tract with the gloved finger from time to time to make sure the tract is going in the right direction.
 - viii. Use the kelly clamp to pop into the chest cavity. The clamp should spread the muscles off the rib above the subcutaneous tract you just made. Then using gentle pressure push the clamp into chest cavity. After the pleural cavity has been entered, insert the gloved finger to explore for adherent lung. Further enlarge the opening in the pleura by inserting a large Kelly or Peon clamp and

spreading it. If you don't have adequate pain control the patient will experience a significant amount of pain with this maneuver and splint. This will close the intercostal spaces on the side that you are trying to insert the chest tube. This will make your job of inserting a chest tube much harder. Pain control is very important.

- ix. Select the tube to be used. Use chest tubes that have centimeter markings. Grasp the tip of the tube with a long Kelly (Peon) clamp so that the long axis of the clamp is almost parallel to the long axis of the tube. Clamp the distal end of the chest tube to avoid blood from going every where.
- x. Insert the tube into the chest using the large Kelly (Peon) clamp as a guide. Insert the chest tube no less than 12 - 14 cms in an adult. Remove the large Kelly (Peon) clamp from the proximal end of the tube as soon as the tube is in the chest about 6 - 8 cms.
- xi. If the lung is adherent to the chest wall and can not be dissected away from the chest wall, ***a chest tube can not be placed through this hole.***
- xii. Connect the tube to the underwater seal chest drainage apparatus.
- xiii. Suture the tube to the skin with a suture of #0 or #1 silk/nylon.
- xiv. Place a Vaseline gauze dressing around the tube.
- xv. Obtain a portable chest X-ray to check the position of the tube.
- xvi. **Avoid the use to trocars** to insert the chest tubes.

PRACTICE GUIDELINES: Pericardiocentesis

OBJECTIVES:

1. To provide indications for the performance of a pericardiocentesis.
2. To provide guidelines for the performance of a needle and open pericardiocentesis.

DEFINITIONS:

1. Needle pericardiocentesis: A procedure in which a needle is placed into the pericardial sac to remove blood that has resulted in a pericardial tamponade.

GUIDELINES:

1. Needle pericardiocentesis:
 - a. Indications:
 - i. Evidence of cardiac tamponade in the face of deteriorating vital signs:
 - (1) Hypotension.
 - (2) Distended neck veins with blue facies.
 - (3) CVP (if measurable) >20 mmHg.
 - (4) Narrowed pulse pressure.
 - (5) No other explanation of hypotension (e.g., pneumothorax).
 - ii. Consider when there is a penetrating injury to the chest.
 - iii. This is not a primary diagnostic procedure.
 - iv. Consider ultrasound as primary diagnostic modality for pericardial tamponade.
 - b. Equipment:
 - i. Long 16 gauge spinal needle, or **preferably** a triple lumen line insertion set which allows guide wire placement to catheter into pericardial space for repeat aspirations

- if necessary
- ii. 30 ml syringe.
- c. Procedure:
 - i. Monitor vital signs: continuous EKG, BP.
 - ii. Prep the subxiphoid area.
 - iii. Puncture the skin just inferior to the left xiphochondral junction, at a 45° angle to the skin.
 - iv. Carefully advance the needle superiorly and toward the inferior tip of the left scapula. Constantly aspirate with syringe.
 - v. Monitor the EKG, looking for evidence of current of injury suggesting advancement into the myocardium. Marked ST-T wave changes, widened QRS complexes or PVCs may indicate current of injury. If these are seen, withdraw needle slightly.
 - vi. Aspirate blood from the pericardial sac. Withdraw as much as possible.
 - vii. If more than 50cc is removed with no hemodynamic improvement, the needle may be in the ventricle.
 - viii. If there has been physiologic improvement, then leave the plastic sheath in place and remove the syringe. Secure the plastic sheath to the skin.
 - ix. Notify the OR immediately and begin making preparations to transfer to the OR for median sternotomy.
- d. Complications:
 - i. Aspiration of ventricular blood rather than pericardial blood.
 - ii. Laceration of coronary artery or vein.
 - iii. Laceration of myocardium.
 - iv. Hematoma.
 - v. Pneumothorax.
 - vi. Infection.

PRACTICE GUIDELINES: Emergency Resuscitative Thoracotomy

OBJECTIVE:

1. Emergency resuscitative thoracotomy may be necessary to salvage patients who present in extremis and might otherwise die without aggressive therapy. **Emergency thoracotomy is not indicated in the resuscitation of all trauma patients who present in extremis.** The following protocol is intended to be a guide and is not intended to be all-inclusive or exclusive. Additional patients not covered by this protocol who might benefit from emergency thoracotomy will be rare and case-specific. The procedure is performed in conjunction with other resuscitative efforts and should not be employed in isolation. ***This procedure should only be undertaken if definitive operative care can/will be rendered as an immediate follow up to the Emergency Resuscitative Thoracotomy.***

DEFINITIONS:

1. Signs of life: Presence of blood pressure, cardiac electrical activity, and respiratory effort.
2. Aggressive fluid resuscitation: Packed RBC 2 units and Lactated Ringers 2 liters or equivalent volume over 15 minutes.

GUIDELINES:

1. Indications:
 - a. Penetrating thoracic trauma with systolic BP <40 mmHg or Pre-hospital signs of life within 15 minutes of arrival to the ED.
 - b. Suspected systemic air embolism.
2. Procedure:
 - a. Rapid bilateral antero-lateral prep while thoracotomy tray opened.
 - b. Left antero-lateral thoracotomy incision located beneath nipple in males and inferior breast fold in females. Incision extends from left sternal border to anterior border of latissimus dorsi. Chest entered along the superior aspect of 4th or 5th rib. Care must be taken to avoid injury to heart and lung. At the same time this procedure must occur quickly. A right antero-lateral thoracotomy may be preferred for primary right chest wounds.
 - c. Additional exposure may be accomplished by extending thoracotomy incision across sternum into contralateral chest cavity.
 - d. Insert rib spreader with handle located toward table laterally.
 - e. Examine pericardium. If tense hemopericardium present then proceed to step “h” below.
 - f. If systemic air embolism is suspected or massive hemorrhage from lung parenchyma or hilum is present, then place Satinsky clamp across hilum medially.
 - g. Retract left lung with left hand. Locate aorta by running right hand medially along posterior chest wall. Aorta located along lateral aspect of vertebral bodies and will be postero-lateral to esophagus. (Naso or orogastric tube helpful in delineating the esophagus) Dissect around aorta inferior to pulmonary hilum and apply aortic cross-clamp.
 - h. Enter pericardium by longitudinally incising pericardium anterior and parallel to phrenic nerve. This is best accomplished by grasping pericardium with forceps and cutting with Metzenbaum scissors. Pericardial incision is carried inferiorly to diaphragmatic reflection and superiorly to level of superior pulmonary hilum.
 - i. Care must be taken to avoid injury to left atrial appendage and phrenic nerve. This is best accomplished by lifting tip of scissors laterally as incision is made.
 - i. Manually lift heart from pericardial sac. If hemopericardium is present, then examine for cardiac perforation. Tamponade perforation with finger or Foley balloon. Teflon pledgetted 3-0 Prolene sutures on a taper needle are present in thoracotomy suture pack for repair of cardiovascular wounds. Consider use of skin stapler. If hemopericardium is not present, then begin open cardiac compression.

PRACTICE GUIDELINES: Peripheral and Central Intravenous Access

OBJECTIVES:

1. To outline the indications and options for intravenous access.
2. To provide guidelines for the performance of procedures to provide emergent intravenous access to trauma patients.

GUIDELINES:

1. In general, intravenous access should be obtained early in the resuscitation of all trauma

patients. The easiest site should be used first, and usually this is the forearm, or antecubital veins. If these are difficult to use, then consideration should be given to alternative sites including:

- a. Femoral vein.
 - b. Subclavian vein.
 - c. Internal jugular vein.
 - d. Saphenous vein:
 - i. At the ankle.
 - ii. At the groin.
2. For trauma patients, the largest IV that is feasible should be used. In peripheral sites, this will be a 14 or 16 gauge intravenous line. For central vein use, this will be a 8.5 - 9 F introducer or large diameter multi-lumen catheter (12 F).
 3. Sterility is important; however, getting the line in is even more important. Do your best to maintain sterile conditions but do not let it impair the urgency with which a line should be inserted.
 4. Placements:
 - a. Peripheral IV:
 - i. Two 14 or 16 gauge angiocath in all adult patients.
 - ii. All IV's should be inserted after adequate skin prep.
 - iii. Peripheral IV's in children should utilize at least an 18 gauge angiocath whenever possible. Avoid placement in injured extremities if possible.
 - b. Femoral venous access:
 - i. Remember: for adequate fluid administration, use appropriately sized catheters.
 - ii. The area is prepped and a syringe is placed on the angiocath.
 - iii. The angiocath or needle is inserted while aspirating the syringe.
 - iv. When blood return is obtained, the catheter is gently inserted into the vein or a wire is placed for introducer insertion.
 - c. Subclavian venous access:
 - i. Procedure:
 - (1) With the patient in mild Trendelenburg, prep and drape the shoulder and chest with towels.
 - (2) Infiltrate the area where the catheter is to be inserted and the clavicular periosteum with 1% lidocaine.
 - (3) Note the landmarks:
 - (a) The junction of medial and middle one-third of the clavicle.
 - (b) The skin is penetrated for approximately 1 cm. After the tip of the needle has reached the clavicle, the inferior border is located by gentle probing and then the needle is advanced posterior to the clavicle. The entire maneuver so far is 1 - 1.5 cm from the skin surface.
 - (c) The direction of the needle is then changed and aimed at the suprasternal notch. At this time, the syringe is almost parallel to the patient's skin surface since the needle has to be as close to the clavicle as possible.
 - (d) While applying gentle suction, the needle is slowly advanced in the

direction of the notch. Upon entering the vein, free flow of blood should be noted.

- (e) The syringe is removed and the gloved thumb promptly applied over the open hub to avoid air embolus.
- (f) The wire, previously placed in readiness, is threaded through the needle and advanced into the right atrium. If any resistance is encountered, STOP! Advance the wire only with care and good judgment.
- (g) The needle is removed from the wire, making sure that the wire is always controlled. A small stab incision is made next to the wire and the dilator placed over the wire. Gentle rotation usually facilitates entry of the dilator into the vein. The dilator is withdrawn and the introducer/dilator unit is inserted over the wire. The dilator is removed.
- (h) The line is then flushed and sutured into place.
- (i) A dressing is applied with sufficient tape so that if someone pulls on the line by mistake, it will not come out.
- (j) Do a stat chest X-ray.

PRACTICE GUIDELINES: Blood and Blood Product Transfusion

OBJECTIVE:

1. To provide guidelines for the transfusion of blood and blood products in trauma patients.

DEFINITIONS:

1. Packed red blood cells: A blood product that contains red blood cells with most of the plasma removed. The average hematocrit of PRBC's is 70%. Each unit of PRBC's (220 ml) will raise the hematocrit by about 3%.
2. Fresh frozen plasma: A blood product that contains fresh components of plasma, including colloid proteins and clotting factors.
3. Platelets: A blood product that contains primarily platelets suspended in a small amount of plasma. Each unit of plasma will raise the platelet count by about 10,000.
4. Cryoprecipitate: A blood product component of plasma that primarily contains Factor VIII, Factor V and fibrinogen. This is the best blood product for treatment of low fibrinogen (<150 mg/dL).

GUIDELINES:

1. Resuscitation in the ED is initiated with warmed LR/NS solution infused through large-bore IV catheters. In hypotensive patients, 2000 ml should be administered as rapidly as possible.
2. Upon initiating resuscitation, send blood sample to the Blood Bank for immediate type and cross. If blood requirements will be excessive, inform the Blood Bank so that back-up resources may be notified.
3. In most situations, LR/NS may be administered until type and cross-matched blood is available. However, situations will arise when O-negative or type-specific blood will be necessary.
4. O negative blood is available immediately. Due to limited supply of O-negative blood, consider O, positive blood for males and sterile or post-menopausal females.
5. Type Specific Blood (Uncross-matched, ABO, Rh compatible blood): available in 10

- minutes after sample received in the Blood Bank.
6. Type and cross-matched: Available in 30 minutes after sample received in the Blood Bank.
 7. Consider autotransfusion:
 - a. Chest tubes with exsanguinating hemorrhage.
 - b. Set up cell-saver compatible chest drainage system
 - c. Abdominal or chest injuries with exsanguinating bleeding.
 - i. Call OR.
 - (1) Make sure that operating room charge nurse is aware that cell-saver system and technician will be needed.
 8. Fresh frozen plasma: available in 15-45 minutes (dependent on thawing equipment).
 - a. Absolute indications:
 - i. Patient with seriously bleeding injury who is clinically anticoagulated on Coumadin. (See Practice Guideline: Anticoagulation/Antiplatelet Reversal.)
 - ii. Documented coagulopathy due to dilution or DIC.
 - iii. Use when transfusing more than 2 units of PRBC's. This helps to prevent the dilutional coagulopathy that can develop when transfusing more than 4 units of PRBC's.
 - (1) Massive transfusion: after the fourth unit of PRBC's and then one unit FFP for every unit of PRBC's. This indication should be modified by anticipated on-going blood loss and evidence of clinical bleeding. The ideal ratio of FFP:PRBC is still being debated in the trauma literature. Currently, a ratio of 1:1 is recommended after the second unit of blood is given.
 - iv. Administer 2 to 4 units as soon as it is available.
 - b. Relative indications:
 - i. Elevated PT/PTT.
 - ii. Severe traumatic brain injury
 9. Platelets: available in 30-45 minutes after sample received in the Blood Bank.
 - a. Absolute indication: evidence of bleeding with a platelet count <50,000.
 - i. Actively bleeding patients on platelet inhibitors. (See Practice Guideline: Reversal Anticoagulation/Antiplatelet)
 - b. Relative indications:
 - i. Potential bleeding with platelet count <20,000.
 - ii. Massive transfusion with non-surgical bleeding before the platelet count can be obtained.
 - iii. Give 6 units of platelets after every tenth unit of PRBC's in massive transfusion. This indication should be modified by platelet count.
 10. Cryoprecipitate: available in 30-45 minutes.
 - a. Absolute indication: non-surgical bleeding with fibrinogen <150 mg/dL.
 - b. Relative indication: non-surgical bleeding after massive transfusion before a fibrinogen level can be obtained.

PRACTICE GUIDELINES: Anticoagulant/Antiplatelet Reversal

OBJECTIVE: To provide guidelines for rapid reversal of anticoagulant and antiplatelet agents

during life threatening bleeds. The benefits of reversing warfarin and platelet inhibitors outweigh the risk of coagulopathy in patients with seriously bleeding injury.

GUIDELINES: Reversal of Warfarin

1. Discontinue Warfarin
2. Vitamin K 10 mg IV in 50 ml D5W at 150 ml/hr x1 now
3. Check INR in 12 hours to evaluate the need to repeat Vitamin K
 - a. **For serious bleeding** consider FFP or Prothrombin Complex Concentrate (Profilnine SD) or Recombinant Factor VIIa (Novo-7) (in addition to Vitamin K)
 - b. **For life threatening bleeding** consider Prothrombin Complex Concentrate (Profilnine SD) or Recombinant Factor VIIa (Novo-7) (in addition to Vitamin K)
4. FFP 10 ml/kg x1 (approx 300 ml per unit)
 - a. Recheck PT/INR 1 hour after infusion of FFP
5. **Prothrombin Complex Concentrate (Profilnine SD)** via syringe IV at 10ml/min x1 now
 - a. If INR <4 and patient weighs < 90 kg, give 1000 units IV (10 ml syringe)
 - b. If INR > 4 or patient weighs > 90 kg, give 2000 units IV (20 ml syringe)
 - c. Recheck PT/INR 30 minutes after infusion of Prothrombin Complex Concentrate (Profilnine SD)
6. **Recombinant Factor VIIa (Novo-7)** 1.2 mg IV over 2-5 minutes x1 now. **NOTE: ALL 3 criteria must be met before consideration of Factor VIIa (Novo-7)***
 - a. Platelet count > 70,000/mm
 - b. Fibrinogen > 100 mg/dl
 - c. Acidosis is absent or has been corrected
 - i. Repeat PT/INR 30 minutes after dose. Bleeding cessation is best measure of outcome.
 - ii. Consider repeat dose if persistent clinical signs of bleeding.

Reversal of Enoxaparin (Lovenox)

1. If < 8 hours since last dose, give 1 mg protamine per mg Enoxaparin x1 STAT
2. If between 8-12 hours since last dose, give 0.5 mg protamine per mg Enoxaparin x1 STAT
3. If > 12 hours since last dose, give no protamine

Reversal of Antiplatelet Medications - Aspirin, Aspirin/Dipyridamole (Aggrenox), Clopidogrel (Plavix), Ticlopidine (Ticlid), Cilostazole (Pletal) [based on recommendations from the following articles - J Trauma. 2009;66:942–950, American Journal of Neuroradiology 29:e97, November-December 2008]

1. Obtain Platelet function assay (PFA-100). Give 1 platelet dose pack if Platelet Function Screen is above normal range.
2. Give Desmopressin 0.3 mcg/kg IV in 100 ml NS over 30 minutes x1
3. With Clopidogrel or Ticlopidine only, add Methylprednisone 20 mg IV x1

CAUTIONS: Rapid reversal of anticoagulation may lead to thrombosis with an increased incidence in patients with a known history of thrombogenic conditions. Reversal of Warfarin with

high doses of vitamin K will preclude re-anticoagulation with warfarin for 7-10 days.

PRACTICE GUIDELINES: MASSIVE TRANSFUSION PROTOCOL

OBJECTIVE: To standardize an approach to large volume resuscitation to attenuate, as possible, coagulopathic abnormalities.

For massive uncontrolled traumatic hemorrhage, maintenance of full hemostatic ability is usually unrealistic. The priority is for definitive surgical arrest of hemorrhage from major vessels. Combinations of packed cells, colloids & crystalloids are given to maintain blood volume or pressure at adequate levels and hemoglobin at around 7g/dl or hematocrit at 25%. Conserve limited supplies of fresh blood, plasma or platelets until the bleeding is controlled if possible.

If on-going and large volume transfusion is anticipated: Notify the Blood Bank as soon as possible of the situation and anticipated need for on-going transfusion of blood and components.

Begin and continue resuscitation utilizing the standard ATLS Guidelines after 4 units of PRBC and with the need for on-going transfusion, utilize Massive Transfusion Protocol Pack for ongoing replacement.

6 u PRBC

4 u FFP

5 single donor platelet packs

10 u cryoprecipitate

Monitor coagulation factor levels as needed. Consider the use of rFVIIa if patient not hypothermic, acidotic and coagulation substrate being replaced.

Remember:

- CONTROL SURGICAL HEMORRHAGE
- PREVENT HYPOTHERMIA
- IN OR, THINK DAMAGE CONTROL LAPAROTOMY, THORACOTOMY, ORTHOPEDICS
- KEEP BLOOD BANK APPRISED OF EVOLVING SITUATION

PRACTICE GUIDELINES: PREVENTION OF HYPOTHERMIA

OBJECTIVE: To define methodologies to prevent hypothermia in the trauma patient.

DEFINITIONS:

1. Hypothermia: A body temperature below normal in any victim of trauma.
2. "Clinical" hypothermia: A core temperature below 35° C in any victim of trauma and is classified as follows:
 - a. Mild hypothermia: 32° to 35° C.
 - b. Moderate hypothermia: 30° to 32° C.

- c. Severe hypothermia: < 30° C.
- 3. Patients at risk for hypothermia:
 - a. History of prolonged, cold environmental exposure.
 - b. Massive blood and fluid loss with large fluid requirements.
 - c. Severe head and spinal cord injury.
 - d. Infants and children.
 - e. Geriatric patients
 - f. Burns.
 - g. Drowning victims.

GUIDELINES:

1. All victims of major trauma are considered at risk for hypothermia.
2. Core temperature should be obtained on all patients with major injuries.
3. The trauma room temperature should always be maintained at greater than 75° F.
4. Avoid prolonged patient exposure, i.e., cover with warm blankets. The operating room should be maintained at 85° F.
5. Warm blankets should be provided to the patient as soon as possible.
6. All fluid going into patient should be warm.
7. For major transfusion requirements, use blood warmer that will infuse the blood rapidly. Alternatively, run warm saline into the bag of packed red cells (Blood on one arm of Y tubing and warm saline on the other arm.) This will warm and thin the packed cells for faster infusion.
8. If hypothermia becomes a problem, obtain the Bair Hugger and apply over as much of the body surface as possible.

The best treatment of hypothermia is to prevent it.

PRACTICE GUIDELINES: TRAUMA ARREST

OBJECTIVES: To define the appropriate priorities in the management of trauma arrest. To define the appropriate procedures for the management of trauma arrest.

DEFINITION:

Trauma arrest: A patient who is admitted to the trauma room with no pulses or spontaneous respiratory activity. This status includes pulseless electrical activity (PEA).

GUIDELINES:

Background: Unfortunately, the overall results with trauma arrest after blunt trauma are very disappointing making prolonged resuscitative efforts futile and painful for the Trauma Team and patient family. Very few patients who are brought to the Emergency Department in a full arrest will ever survive. With penetrating injuries, particularly the chest, the prognosis is somewhat better, although the results are only remarkably good at major urban trauma centers at which the pre-hospital transport times are very short.

1. Blunt traumatic arrest: For blunt trauma the following steps are recommended (this assumes that the patient truly is arrested and has no spontaneous cardiac or respiratory activity):
 - a. Transfer patient onto trauma gurney. Continue CPR.
 - b. Obtain from EMS an accurate history regarding the mechanism of injury and the duration of absence of vital signs. Resuscitation may be terminated if no signs of life for 10 minutes. If the resuscitation is to be continued, the following sequence is recommended:
 - c. Do a rapid Primary Survey. Confirm presence or absence of spontaneous cardiac and/or respiratory activity.
 - d. Do simultaneous orotracheal intubation and IV access. In this situation IV access may not be obtainable in peripheral veins. If this is the case, then attempt subclavian/femoral vein IV insertion.
 - e. Insert 14-gauge IV catheter into the second intercostal space in the midclavicular line in both sides of the chest. Make sure that the needles puncture into the pleural space, leaving the plastic cannula in place. If a large amount of air or blood is obtained out of either cannula, then immediately insert a 36-40 Fr. chest tube into that side of the chest. Alternatively, insert chest tube on both sides of the chest as initial procedure.
 - f. As the above procedures are being carried out, place EKG electrodes on the patient and assess the cardiac rhythm. Next, initiate the ACLS protocol. In the usual case, the problem will be asystole and atropine/epinephrine will be the first drugs of choice.
 - g. Run IV's at a full open rate with pressurized bags.
 - h. If available, perform ultrasound examination of heart for pericardial effusion and cardiac activity.
 - i. By this time, the resuscitation should have been ongoing for about 5 minutes. If there is no return of electrical activity, terminate the resuscitation.
2. Penetrating chest injury resulting in trauma arrest:
 - a. The patient who arrives in trauma arrest with a penetrating injury has a better prognosis and deserves vigorous trauma resuscitation. The Team Leader must determine from pre-hospital providers the patient's vital signs at the scene and en route to the hospital. If the patient had no vital signs at the scene, then successful resuscitation is less likely. If the patient had vital signs at the scene or en route to the hospital, then undertake a full trauma resuscitation using full resuscitative techniques.
 - b. This involves the following protocol:
 - i. Transfer the patient to the trauma gurney and immediately listen for breath sounds. Define vital signs from the field.
 - ii. For cardiac arrest patients with field vital signs or patients with cardiac activity and BP < 40, simultaneously intubate the patient and start large-bore IV's. Once the IV's are in place, apply pressure bags to increase the rate of IV infusion of lactated ringers. Decompress either side of the chest with absent breath sounds with either a needle thoracostomy or chest tube.
 - iii. NOTE: The following should be undertaken only if trained, experienced personnel are available and definitive repair of pathology can be accomplished. Indeed, this procedure is best done in the OR if at all possible. See **Practice Guideline: Emergency Resuscitative Thoracotomy**. Prepare immediately for a left thoracotomy, and perform this procedure if the patient does not respond immediately to external cardiac massage, the first part of the ACLS protocol, and intubation. At

thoracotomy, look for any major bleeding points and look to see if the pericardium is full of blood, cross clamp the descending thoracic aorta just above the diaphragm. If the pericardium appears to contain blood, then open the pericardium anterior to the phrenic nerve, evacuate the blood from around the heart and digitally occlude the wound in the heart. Maintain internal cardiac massage while this is being done. If the bleeding is from the hilum of the lung, place a large Satinsky clamp across the hilum. If control of the bleeding from the heart cannot be maintained from the left thoracotomy or the injury is on the right side of the chest, then using a large pair of Mayo scissors cut across the sternum transversely at the level of the thoracotomy. Be aware the internal mammary vessels will be transected in this maneuver.

- iv. At the time of the thoracotomy, immediately notify the OR as well as the Blood Bank. Cardiac/Thoracic Surgery should also be notified.
3. Penetrating abdominal injury resulting in trauma arrest:
 - a. If the patient has a penetrating wound to the abdomen and arrives without vital signs but had recent vital signs per EMS and does not respond to initial resuscitation, then prepare to do a left thoracotomy in order to clamp the lower thoracic aorta. Continue internal cardiac massage as the clamp is being placed. Try to resuscitate the patient with fluids and the ACLS protocol. If this is successful, prepare the patient immediately for the OR in order to control the intra-abdominal hemorrhage. Leave the clamp on the aorta until the abdomen is open and evacuated of all blood.
 - b. If no obvious injuries can be found at thoracotomy, or if the patient does not respond to containment of the bleeding, then continue the resuscitation for 10-15 more minutes to make sure that the bleeding cannot be controlled or that the heart does not respond. At that time, discontinue resuscitation efforts.

PRACTICE GUIDELINES: MANAGEMENT OF TRAUMATIC BRAIN INJURY

OBJECTIVE: To provide guidelines to help standardize the diagnosis and early management of traumatic brain injury.

Refer to Guidelines for the Management of Severe Head Injury Published by the Brain Trauma Foundation in 1995. This is the current state of the art, evidence based approach to traumatic brain injury. See Also www.east.org Practice Guidelines Management of Mild Traumatic Brain Injury.

DEFINITION: Traumatic brain injury: An injury to the brain resulting in disorders of motor, sensory and/or cognitive function.

GUIDELINES:

1. Perform primary survey according to ATLS guidelines:
 - a. Provide urgent airway for GCS .8. Hypoxia is devastating to the injured brain.
 - i. If sedatives and paralytics are to be used, conduct a rapid but thorough neurologic exam, including:
 - (1) Level of consciousness.
 - (2) Ability to verbalize.
 - (3) Ability to open eyes.
 - (4) Ability to move all extremities to verbal command or pain.

- (5) Presence of abnormal posturing.
 - (6) Presence of abnormal reflexes.
 - (7) Presence of rectal tone if unable to move lower extremities (if feasible).
 - (8) Pupillary response.
 - (9) Gag reflex.
- ii. Maintain C-spine precautions including rigid collar.
- b. Check for chest injury; ventilate to maintain $pCO_2 = 35-40$ mmHg.
 - c. Determine hemodynamic status, resuscitate from shock with Lactated Ringers solution. Maintain normovolemia and normal hemodynamics.
 - d. Expose patient, when able, to look for any non-obvious injury.
2. Rapid Sequence Induction to Intubation for brain injured patients.
 - a. Preoxygenate, monitor SaO₂.
 - b. All equipment out, tested and readily available. This should include equipment for back up airway if unable to intubate.
 - c. Maintain manual in-line cervical immobilization. Will need to remove cervical collar to adequately open mouth for intubation.
 - d. Maintain cricoid pressure until tube position confirmed.
 - e. Lidocaine 1 mg/kg IV
 - f. Adequate analgesia/sedation as indicated with morphine/fentanyl or versed/etomidate.*
 - g. Succinylcholine 1-1.5 mg/kg IV*
 - h. Vecuronium 0.1 mg/kg IV to maintain neuromuscular blockade after intubation.*
 - i. If long acting neuromuscular blocker is to be utilized, the patient must receive scheduled analgesia and sedation.
- *The choice of medications utilized should be determined by the intubating physician or paramedic. He/she should use the medications with which he/she is most familiar. All drug regimens should have: lidocaine, analgesia, sedation, short duration neuromuscular blocking agent and perhaps intermediate duration neuromuscular blocking agent.
3. Resuscitate patient as above until hemodynamic and pulmonary stability is achieved.
 4. Calculate the pre intubation Glasgow Coma scale. GCS can non be determined on pharmacologically relaxed patient.
 5. Obtain a head CT scan:
 - a. GCS ≤ 14 .
 - b. Any patient with focal neurologic deficit.
 - c. Any patient with witnessed loss of consciousness > 5 minutes.

NOTE: CT brain is not necessary prior to transfer if clinical examination dictates rapid transfer. This is especially true if obtaining a CT will delay transfer.

1. CT priorities:
 - a. CT should be abandoned if patient requires emergent operation to stop hemorrhage or immediately repair life-threatening injury. Notify neurosurgery immediately of this situation.
 - b. CT should be obtained, otherwise, to determine presence of space-occupying clot prior to

- other surgeries.
2. Sedation:
 - a. Uncooperative or thrashing patients should be treated with sedation.
 - b. Morphine 0.1 mg/kg IV if associated with painful injury.
 - c. Versed 0.1 mg/kg IV for agitation.
 - d. If intubated, pancuronium or vecuronium 0.1 mg/kg IV or cisatracurium 0.2 mg/kg IV if sedation is not satisfactory to allow ventilatory control or cooperation with the diagnostic studies. **Do not give paralyzing agent without associated pain medications and sedative.**
 3. Hyperventilating to pCO₂ below 30 mmHg without appropriate monitoring may result in cerebral ischemia and worsening of secondary brain injury. This is to be avoided and uncontrolled hyperventilation (p CO₂ < 35 mmHg) is no longer recommended.
 4. Seizures:
 - a. Administer Ativan 0.1 mg/kg boluses repeatedly until seizure breaks. Be prepared for respiratory depression.
 - b. Prophylaxis with Dilantin 15 - 20 mg/kg at a rate not to exceed 50 mg/min or fosphenytoin (Cerebyx) 15 - 20 mg given at rate not to exceed 150 mg/min.
 - i. Administer if seizure has occurred.
 - ii. Consider administration if there is a high likelihood of post-traumatic seizure.
 - (1) Penetrating injury.
 - (2) Skull fracture with depression.
 - (3) Intraparenchymal hematoma.
 - iii. Mannitol: at the discretion of the Neurosurgeon, a mannitol bolus of 0.5 - 1 gm/kg can be given for evidence of rising intracranial pressure. Mannitol should not be used in hemodynamically unstable patients. Mannitol should be reserved for patients with impending herniation.

AVOID AT ALL COSTS -

1. Hypotension
2. Hypoxia
3. Hypocarbica
4. Hypoglycemia
5. Hypercarbia
6. Hyperglycemia
7. Hyperthermia

PRACTICE GUIDELINES: NECK IMMOBILIZATION PRIOR TO CERVICAL SPINE CLEARANCE

OBJECTIVES: To define appropriate methods for cervical spine immobilization prior to clearance.

DEFINITIONS: Cervical spine immobilization: Use of a device to stabilize the neck in a neutral position until adequate evaluation can be undertaken to determine the presence or absence of cervical spine injury. Cervical spine clearance: See Practice Guideline: C-spine clearance.

GUIDELINES:

1. All patients who have a mechanism for possible cervical spine injury and are being evaluated must be treated with cervical spine immobilization, including: Log roll if suspicion of cervical, thoracic, lumbar or sacral spine injuries. Cervical immobilization collar.
2. Unless the patient is to be transferred to the Trauma Center immediately, the patient should be log rolled, with manual immobilization of the head and neck, off of the long spine board onto a “smooth mover” type device, which should be on the ED stretcher prior to patient arrival. During the log roll, the back should be inspected/palpated and clothing/debris removed from behind the patient. The purpose of this maneuver is to maintain a firm surface for the spine, improve the quality of X-rays shot through the device and minimize the risk of pressure necrosis from prolonged periods on the long spine board. Most patients will arrive to the trauma room with a cervical collar in place. Make sure the collar has been applied correctly. Check under the collar (with manual immobilization) for the presence of lacerations, swelling, penetrating injuries, tracheal deviation, subcutaneous emphysema or distended neck veins. Make sure that the collar is appropriately padded around lacerations or other open wounds.
3. Proceed with C-spine clearance protocol.
4. If cervical spine injury cannot be ruled out in less than 8 hours, then change the cervical collar to an appropriately sized Aspen or similar collar.

PRACTICE GUIDELINES: CERVICAL SPINE CLEARANCE

OBJECTIVE: To provide guidelines for the diagnostic evaluation of the cervical spine in patients suffering multiple injuries who are at high risk for cervical spine injuries.

NOTE: There is no current standard, universally accepted, evidence based protocol for the clearance of the cervical spine. Please refer to www.east.org “Practice Parameters for Identifying Cervical Spine Injuries Following Trauma” section for a detailed and excellent literature review of this topic.

DEFINITION:

1. C-Spine: Includes C1 to the upper border of T1.
2. Clearance of C-Spine: A **clinical decision** confirming the absence of acute bony, ligamentous and neurologic abnormalities of the cervical spine based on history, physical exam and/or negative radiologic studies.

GUIDELINES:

1. Patients should be considered to have a cervical spine injury if they present with any of the following conditions:
 - a. A history of blow to the head or neck.
 - b. Pain in the cervical spine or paraspinous muscles.
 - c. Pain to palpation of the cervical spine.
 - d. Traumatic brain injury and/or skull fracture.
 - e. Facial injuries such as fractures, tooth loss or severe lacerations.
 - f. Neurologic deficits in torso, legs or arms not explained by peripheral nerve injuries.

2. Awake patient without cervical tenderness:
 - a. A patient with possible C-spine injury as defined in Section 1 above (usually based on mechanism) may have their cervical spine cleared without further radiologic evaluation if all of the following conditions exist:
 - i. No neck pain.
 - ii. No pain to palpation of cervical spine or paraspinous area.
 - iii. Awake and alert.
 - iv. No significant distracting pain.
 - v. No associated injuries suggesting serious C-spine injury.
 - vi. No pain with active range of motion of the neck.
 - vii. No drug or alcohol intoxication
 - b. If the cervical spine is cleared under these conditions, there must be appropriate documentation in the chart.
3. Awake patient with tenderness:
 - a. A patient with possible cervical spine injury as defined in Section 1 above associated with cervical tenderness should be evaluated as follows:
 - i. Obtain a full cervical spine series: AP, lateral, swimmer's view, open mouth odontoid. Trauma oblique views can be added. Films done in the Radiology Department are generally of much higher quality than portable films in the ED.
 - ii. If the above films are negative, it will be the decision of the evaluating physician to clear the spine, obtain consultation or proceed with flexion/extension views, CT scan of the cervical spine or MRI. There is no evidence-based literature to support one approach over another.
 - iii. CT scanning has clearly replaced plain radiography in the clearance of cervical spines at most Trauma Centers.
 - iv. Plain radiographs and CT scanning are used to detect bony injury. Flexion/extension views and MRI are used to detect ligamentous injury "Clearing" a cervical spine is a balance of clinical information considering mechanism of injury and physical coupled with some or all of the above radiologic studies.
 - v. If plain radiographs are suspicious, equivocal or uninterpretable, a CT scan should be obtained through the area of discomfort to further evaluate bony anatomy.
 - vi. If X-rays suggest bony or ligamentous abnormalities or instability, then consult Neurosurgery or Orthopedic Surgery.
 - vii. Consider an MRI in the high risk pediatric patient.
4. The patient with altered mental status and possible C-spine injury:
 - a. The patient has a head injury or intoxication and cannot provide a reliable clinical exam:
 - i. Obtain a CT of the cervical spine.
 - ii. If X-rays are negative per the attending radiologist, leave cervical collar in place until patient awakens, and examine for cervical tenderness. If the patient has cervical tenderness, then proceed with flexion/extension views, MRI as indicated.
 - iii. If the patient has no cervical tenderness, then remove the collar and document clearance in chart.
 - iv. CT scanning of the entire cervical spine with sagittal reconstruction may be helpful

in determining when to remove the cervical collar in patients not expected to be able to provide a reliable examination.

CAUTION: The CT scan may miss ligamentous injuries with no associated bony fractures.

5. If any abnormalities are found on any of the radiographs, consult neurosurgery/orthopedic surgery for advice on the next appropriate radiologic procedure. The cervical collar should be kept in place and spinal precautions maintained.
6. If there are any neurologic deficits attributable to a possible cervical spinal cord injury, consult Neurosurgery for advice on the appropriate radiologic studies. The cervical collar should remain in place and spinal precautions observed.
 - a. CT scanning with sagittal reconstruction of the cervical spine is indicated.
 - b. If no bony abnormalities are seen, then obtain an MRI scan to determine spinal cord abnormalities.

SUMMARY:

Patients who require radiologic clearance will follow these guidelines:

The spine remains immobilized in neutral position at all times. The cervical collar is briefly removed in the Emergency Department with manual stabilization of the head to inspect and palpate the neck and then is reapplied. The patient is promptly log rolled off the long spine board and laid onto a Smooth Mover type device. This device is placed on the ED stretcher prior to patient arrival. Appropriate padding of the occiput and shoulder should be utilized to maintain neutral alignment of the spine. The patient then proceeds to Radiology for the appropriate studies. At no time is the cervical collar removed. At no time is the patient placed in the lateral position. At no time is the spine taken out of neutral position. At no time is the patient removed from the Smooth Mover type device unless flexion/extension views are to be performed. The patient is returned to the Emergency Department. The spine is then cleared or not cleared based on the mechanism of injury, the physical examination and the radiologic studies. Only the Emergency Medicine Physician, the Trauma Surgeon, the Neurosurgeon or the Orthopedic Spine Surgeon using all of the above specified information discontinues spinal immobilization.

IMMOBILIZATION CANNOT BE DISCONTINUED ON THE BASIS OF A RADIOLOGIC STUDY ALONE.

PRACTICE GUIDELINES: TRAUMATIC TETRAPLEGIA OR PARAPLEGIA

OBJECTIVES:

1. To define diagnostic approaches to spinal cord injuries.
2. To define early therapeutic intervention strategies for spinal cord injuries.

DEFINITIONS:

1. Traumatic tetraplegia: Any injury associated with a spinal cord or nerve root deficit involving the cranial nerves above and including C8, T1 roots.
2. Traumatic paraplegia: Any injury associated with a spinal cord or nerve root deficit below and including T2.
3. Complete: Any spinal cord injury associated with a complete motor and sensory deficit below the level of the injury.

4. Incomplete: Any sensory or motor sparing below the level of injury including perianal sensation.

GUIDELINES:

1. Follow the ABC's.
2. Perform a complete neurologic exam looking for the presence and level of neurologic deficit.
3. Maintain spine precautions.
4. Obtain CT's according to the C-spine and Thoracic and Lumbosacral injury Guidelines.
5. If tetraplegia or paraplegia are noted, perform a bulbocavernosus reflex test:
 - a. Male: pull on penis or Foley catheter while examining for an increase in rectal tone.
 - b. Female: pull on Foley catheter while examining for an increase in rectal tone.
 - c. If this reflex is present, then spinal shock is not occurring and injury will usually not improve.
 - d. If this reflex is absent, then spinal shock may be occurring and ultimate outcome of injury is masked.
 - e. Document presence or absence of bulbocavernosus reflex.
6. With any injury referable to the spinal cord, start the "steroid protocol" only after consultation with NeuroSurgery:**
 - a. Solu-Medrol 30 mg/kg, IV over 15 minutes (begin as early as possible) within eight hours of injury.
 - b. SoluMedrol 5.4 mg/kg/hr for the next 23 hours.

** There is *considerable disagreement* in the Neurosurgical/Trauma community regarding the utility of high dose steroids in spinal cord injury. The literature does not support efficacy. Knowing the practice patterns of the local Neurosurgeons is necessary.

7. Arrange for immediate transfer to the Trauma Center.
8. Neurogenic shock may occur with injuries as low as T4-6.
 - a. Place Foley and monitor urine output.
 - b. Follow frequent blood pressures.
 - c. If patient has SBP <90 mmHg or MAP <65 mmHg and hemorrhagic shock has been ruled out (by CXR, DPL, FAST or CT scan of the abdomen/pelvis):
 - i. Administer 2000 ml IV fluid.
 - ii. Start dopamine at 5 mcg/kg/min; continue fluid resuscitation as necessary.
 - iii. If no response, increase dopamine to 10 mcg/kg/min.
 - iv. Insert pulmonary artery catheter or central venous line to assess filling pressures and cardiac index.
 - v. Consider phenylephrine starting at 30 mcg/min if filling pressures and cardiac index are satisfactory.
9. For tetraplegic patients with potential pulmonary problems:
 - a. Nearly all patients with a C-5 or higher neuro deficit will require intubation.
 - b. Assess ability to clear secretions: consider intubation if secretions cannot be cleared spontaneously or with quad cough maneuver.
 - c. If there is a question about retention of secretions or development of atelectasis in the first 24 hours, intubate.

10. Provide DVT prophylaxis after consultation with the NeuroSurgeon (see Practice Guideline: DVT Prophylaxis).
11. Keep the patient warm and prevent hypothermia.
12. Request full rehab services consult on admission.

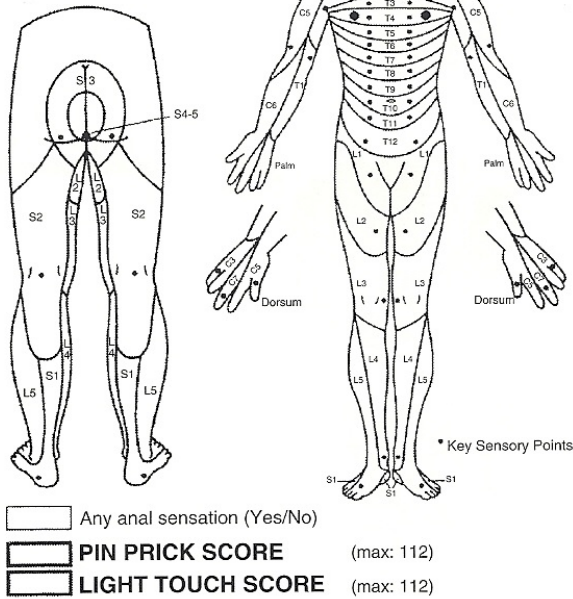
Level	Muscle Group	Action	DTR
C5	Deltoid, spinati	Abduction of shoulder; external rotation of arm	
C6	Biceps, brachialis	Flexion of elbow	Biceps jerk
C7	Triceps, wrist extensors	Extension of elbow, wrist	Triceps jerk
C8	Intrinsic hand muscles	Abduction, adduction of fingers	
L2,3	Iliopsoas	Hip flexion	
L4	Quadriceps	Extension of knee	
L5	Tibialis anterior and posterior, extensor hallucis longus	Dorsiflexion of foot and bit toe	Knee jerk
S1	Gastrocnemius	Plantar flexion of foot	Ankle jerk
S4-5	Anal sphincter	Voluntary contractions of anal sphincter	

Table 1. Major Motor Levels

SENSORY

KEY SENSORY POINTS

0 = absent
 1 = impaired
 2 = normal
 NT = not testable



PRACTICE GUIDELINES: THORACIC AND LUMBOSACRAL SPINE INJURIES

OBJECTIVES:

1. To define patients in which evaluation of the lower spine must be undertaken.
2. To define early intervention of lower spine injuries and prevent neurologic deterioration.

DEFINITIONS:

1. Stable spine injury: Those injuries not associated with a neurologic deficit and not at risk for development of neurologic deficit and not prone to late collapse (e.g., transverse process fractures, spinous process fracture, minimal compression fracture).
2. Unstable spine injury: Any fracture pattern associated with a neurologic deficit and those that are prone to develop a neurologic deficit or those prone to late collapse (e.g., fracture subluxation and dislocation, severe burst fractures).

GUIDELINES:

1. Follow ABC's.
2. Secondary survey:
 - a. Log roll patient with full C-spine immobilization to determine areas of tenderness in the thoracic and lumbosacral spine. If tenderness is present, assume the spine to be unstable.
 - b. If transfer is not imminent, remove long spine board and roll patient back onto Smooth Mover type device. Refer to Cervical Spine Clearance Practice Guideline.
 - c. Examine for areas of increased kyphosis or spinous process step-off.

- d. Perform neurologic exam to determine any deficits suggestive of neurologic injury.
3. Plain x-rays for the most part are difficult to obtain and relatively poor quality. If you are worried about a thoracic or lumbar spine injury and the patient is stable, obtain a CT scan of the thoracic and/or lumbar spines.
4. If neurologic injury is found without bony injury, obtain an MRI scan of the involved spine.
5. Consult Neurosurgery or Orthopedics accordingly.
6. Maintain spinal precautions until cleared by the consulting service.
7. If appropriate discuss the steroid protocol (See "Tetraplegia and Paraplegia") with Neurosurgery if complete or incomplete neuro deficit is found.

If fracture is noted in one area of spine, complete C/T/LS spine CT should be obtained to assess additional fractures. (Please refer to www.east.org for a more complete review of this topic.)

PRACTICE GUIDELINE: BLUNT ABDOMINAL TRAUMA (ULTRASOUND CERTIFIED RESUSCITATION TEAM)

OBJECTIVES: To define the patient that might have significant intra-abdominal injury after blunt trauma. To define appropriate diagnostic approaches to determine intra-abdominal injury. To define strategies for patients with blunt abdominal trauma, with a particular focus on the use of ultrasound to diagnose intra-abdominal injuries.

DEFINITIONS:

Ultrasound Certified: (Mission Hospitals Credentialing Criteria) A certification documenting the completion of the basic ultrasound course and successful clinical experience in 50 ultrasound studies for abdominal trauma.

FAST Exam: An ultrasound examination of the abdomen that utilizes a 4-view approach for the diagnosis of blood or fluid in the abdominal cavity as well as a view of each hemithorax.

GUIDELINES:

Evaluate and resuscitate per ABC priority. The FAST exam is a component of evaluation of "C" circulation determining the presence/absence intra-abdominal hemorrhage and occurs in the Primary Survey of unstable patients.

Perform physical examination of the abdomen, flank and back exams.

Consider the possibility of abdominal injury in the following situation:

1. Obvious abdominal pain with or without peritoneal findings on physical examination.
2. Significant external findings on the abdominal wall such as deformed contusion, bleeding, and laceration.
3. Pelvic fracture.
4. Lower rib fractures.
5. Lumbar or low thoracic spine fractures.
6. Unexplained hemorrhage, shock or blood loss.
7. A history of abdominal impact (e.g., deformed steering wheel, passenger compartment

damage) in a patient with altered sensorium.

8. Drugs and alcohol impairment.
9. Tetraplegia, paraplegia.
10. Traumatic brain injury.

If the patient has indications of abdominal injury and has unstable vital signs, perform a FAST exam. If positive, go to the operating room for exploratory laparotomy. If negative, consider other causes of hemorrhage resulting in hemodynamic instability. If the patient has an indication of possible abdominal injury and has stable vital signs: Perform abdominal CT scan.

NOTE: All abdominal CT scans done for trauma are to be done with IV contrast and are to include the pelvis (the use of oral contrast is facility dependent). If CT scan shows solid organ injuries, then admit the patient for observation. (See Practice Guidelines for Non-operative Management of Spleen and Liver injuries.) If CT scan shows no solid organ injuries but reveals abdominal fluid, then perform DPL or explore or admit for very close observation of possible bowel or mesenteric injury.

PRACTICE GUIDELINES: BLUNT ABDOMINAL TRAUMA (FOR NON-ULTRASOUND CREDENTIALLED RESUSCITATION)

OBJECTIVES: To define appropriate diagnostic approaches to determine intra-abdominal injury.

GUIDELINES:

1. Treat the ABC's first. The determination of intra-abdominal hemorrhage is part of the evaluation of "C" circulation and occurs in the Primary Survey of unstable patients. In stable patients, determination of intra-abdominal injury occurs in the Secondary Survey.
2. Perform physical exam of the abdomen, flank and back exam.
3. Consider the possibility of intra-abdominal injury in the following situations:
 - a. Obvious abdominal pain with or without peritoneal findings on physical examination.
 - b. Significant external findings on the abdominal wall such as ecchymosis, bleeding or abrasions.
 - c. Pelvic fracture.
 - d. Lumbar or low thoracic spine fractures.
 - e. Unexplained hemorrhagic shock or blood loss.
 - f. A history of abdominal impact (e.g., bent steering wheel, passenger compartment damage) in a patient with altered sensorium or when serial physical exams cannot be performed.
 - g. Drugs and alcohol impairment.
 - h. Quadriplegia, paraplegia.
 - i. Traumatic brain injury.
4. If the patient has potential of abdominal injury and has unstable vital signs:
 - a. Perform diagnostic peritoneal lavage.
 - b. If positive, go to the operating room for exploratory laparotomy.
 - c. If DPL is negative, search for other sources of blood loss. DPL will not detect injury to retroperitoneal structures.

5. If the patient has an indication of abdominal injury and has stable vital signs:
 - a. Obtain abdominal CT scan with IV contrast
 - b. Oral contrast is *not* necessary
 - c. Consider DPL or laparotomy after CT scan if:
 - i. Fluid in the abdomen without solid organ injury or pelvic fracture (i.e., probable mesenteric bleeding).
 - ii. There is evidence of mesenteric or bowel wall thickening (possible perforated hollow viscus).
 - iii. Focal fluid collection not explained by solid organ injury (possible perforated hollow viscus).

PRACTICE GUIDELINES: FOCUSED ABDOMINAL ULTRASOUND FOR TRAUMA (ULTRASOUND FAST EXAM)

OBJECTIVES:

1. To provide indications for possible abdominal trauma which would necessitate the performance of an urgent abdominal ultrasound in the trauma resuscitation area.
2. To provide guidelines for the FAST exam for abdominal trauma.

DEFINITION:

FAST Exam: An ultrasound examination of the abdomen that utilizes the four-view approach for the diagnosis of blood or fluid in the abdominal cavity plus additional views of each hemithorax.

GUIDELINES:

The FAST examination is generally utilized as a substitute for diagnostic peritoneal lavage but just like DPL FAST is very sensitive. The purpose is to detect free fluid in the abdomen. A little bit of free fluid is usually not an indication for surgery. A lot of free fluid is an indication for surgery. The CT scan remains the diagnostic modality of choice for intra-abdominal trauma in hemodynamically stable patients.

1. Absolute indications for abdominal ultrasound:
 - a. A comatose hypotensive patient who has no obvious reason for their hypotension
2. Relative indications for abdominal ultrasound:
 - a. Obvious abdominal pain with or without peritoneal findings on physical examination.
 - b. Significant external findings on the abdominal wall such as contusion, bleeding, laceration.
 - c. Pelvic fracture.
 - d. Fractures present above and below the diaphragm.
 - e. Lower rib fractures.
 - f. Lumbar or low thoracic spine fractures.
 - g. Unexplained hemorrhagic shock or blood loss.
 - h. A history of abdominal impact (e.g., deformed steering wheel, passenger compartment damage) in a patient with altered sensorium or not monitored.
 - i. Drugs and alcohol impairment.

- j. Quadriplegia, paraplegia.
 - k. Traumatic brain injury with coma.
 - l. Prolonged non-abdominal surgery requiring anesthesia.
3. All ultrasound examinations are performed with the patient in the supine position.
 4. Bring the ultrasound machine to the bedside.
 - a. Make sure the power cord is plugged in.
 - b. Follow instructions that will be posted on the machine.
 5. Expose the thoracoabdominal area.
 6. Warmed, water soluble transmission gel is applied to the skin in the six positions to be examined.
 7. The following examinations will be performed:
 - a. Pericardial area:
 - i. The transducer position is subxiphoid
 - ii. Identify the heart and, using blood as the standard, adjust the acoustic power, depth and gain.
 - iii. The longitudinal axis (sagittal section) is used to identify the heart and examine for blood in the pericardial region.
 - iv. The normal examination of the heart shows a single echogenic (white) line, representing the pericardium, which separates the cardiac chambers and the liver.
 - v. The abnormal exam shows a separation of visceral and parietal pericardium by a fluid stripe.
 - b. Right upper quadrant:
 - i. The transducer position is in the right mid-axillary line between the 11th and 12th rib.
 - ii. The transducer is oriented longitudinally to obtain a sagittal section of the liver, kidney and diaphragm.
 - iii. Evaluate for fluid in Morison's pouch.
 - c. Right thoracic cavity:
 - i. The right hemidiaphragm and right pleural space are evaluated from the right mid-axillary line by angling the probe superiorly.
 - ii. The diaphragm appears as a curved white stripe that will move with respiration.
 - iii. Normal lung parenchyma appears as an indistinct gray area.
 - iv. Fluid in the pleural cavity appears as a wedge shaped anechoic area just above the diaphragm.
 - d. Left upper quadrant:
 - i. The transducer position is in the left posterior axillary line between the 10th and 11th ribs.
 - ii. The transducer is oriented longitudinally for a sagittal section of the left kidney and spleen.
 - iii. Evaluate for fluid in the splenorenal recess.
 - iv. Evaluate for fluid in the space between the spleen and the diaphragm.
 - e. Left thoracic cavity:
 - i. The transducer position is in the left posterior axillary line with the probe angled superiorly.

- ii. The diaphragm appears as a curved white stripe that will move with respiration.
 - iii. Normal lung parenchyma appears as indistinct gray area.
 - iv. Fluid in the pleural cavity appears as a wedge shaped anechoic area just above the diaphragm.
- f. Pelvis:
- i. The transducer is oriented for coronal sections and placed in the midline approximately 4 cm superior to the symphysis pubic.
 - ii. The normal examination demonstrates the full bladder as an anechoic structure.
 - iii. The abnormal examination will show a hematoma on the right or left side of the bladder.

PRACTICE GUIDELINES: DIAGNOSTIC PERITONEAL LAVAGE

OBJECTIVES:

1. To provide the indications for a diagnostic peritoneal lavage.
2. To provide a guideline to help in the performance of a diagnostic peritoneal lavage.

GUIDELINES:

1. Indications:
 - a. Hemodynamically unstable patients with an altered level of consciousness or para/quadruplegia with the possibility of abdominal trauma.
 - b. Suspected abdominal trauma, associated with hemodynamic instability, especially if abdominal tenderness is present.
 - c. Assessment for possible occult hollow viscus injury.
2. Contraindications:
 - a. Obvious need for laparotomy.
3. Relative contraindications:
 - a. Previous abdominal surgery
 - b. Pregnancy
4. Procedure: This procedure should be performed by the surgeon responsible for the care of the patient.
 - a. NG/OG and Foley catheter unless absolutely contraindicated in unstable patient.
 - b. The area below the umbilicus is scrubbed with povidone-iodine solution or chlorhexidine and draped appropriately.
 - c. The midline area below the umbilicus is infiltrated with 1% Xylocaine with epinephrine.
 - d. An adequate incision is then made in the midline, just below the umbilicus (with severe pelvic fracture or pregnancy, incision is just above the umbilicus in the midline).
 - e. The incision is carried down to the fascia, which is incised longitudinally, exposing the peritoneum. Careful hemostasis must be maintained, as bleeding from the wound may give a false positive tap by contaminating the peritoneal cavity with blood.
 - f. Pick up the peritoneum between two clamps and, while holding the peritoneum, Incise the peritoneum for a distance of 2-4 mm.
 - g. Gently advance the dialysis catheter into the abdominal cavity along the anterior

- abdominal wall. Aim the catheter to the right pelvic gutter.
- h. Aspirate the catheter, and if no or < 10cc of blood returns, Infuse 1000 cc of warmed crystalloid solution in an adult (10 ml/kg for a pediatric patient).
 - i. Lower the empty infusion bag to the floor and allow the fluid to return to the bottle, making sure there is no one-way back flow valve in the IV tubing in use.
 - j. If fluid does not return, twist catheter to unplug omentum from it. If return is still poor, infuse another liter of fluid (reduce cell count threshold by half).
 - k. Send off appropriate mixed fluid to lab for cell count. Remove catheter, close fascia and skin.
5. Results: a DPL is positive for blunt trauma under the following conditions: Gross blood >10 ml Cell count: >100,000 RBC/mm³. >500 WBC/mm³. Food particles or stool. Results: a DPL is positive for penetrating trauma under the following conditions: Gross blood >5 ml. Cell count: >5,000 RBC/mm³. >500 WBC/mm³.

PRACTICE GUIDELINES: PENETRATING ABDOMINAL TRAUMA

Refer to www.east.org "Practice Management Guidelines for Prophylactic Antibiotics in Penetrating Abdominal Trauma" and "Penetrating Intraperitoneal Colon Injuries"

OBJECTIVE: To define appropriate diagnostic and therapeutic guidelines for the diagnosis of penetrating abdominal wounds.

DEFINITIONS:

Penetrating abdominal injury: Any penetrating injury that could have entered the peritoneal cavity or retroperitoneum inflicting damage on the abdominal contents. In general, the entry wounds for an abdominal injury extend from the fifth intercostal space to the perineum. *Anterior penetrating abdominal injury:* An entry wound on the anterior abdomen or chest that could have penetrated into the peritoneal cavity.

Thoracoabdominal penetrating abdominal injury: An entry wound below the fifth intercostal space and above the costal margin. These are wounds that could have initially entered the chest and then penetrated the diaphragm to enter the abdomen.

Posterior or flank penetrating abdominal injury: An entry wound posterior to the posterior axillary line. Wounds in this area are difficult in that the most likely organs to be injured will be in the retroperitoneum. Additionally, the large mass of flank and back muscle will make the diagnosis of organ injury more difficult and the possibility of organ injury less frequent.

GUIDELINES:

1. Follow the ABC's, and resuscitate patient according to findings of the primary survey.
2. Assess the chest and abdomen looking for entry wounds, bleeding and peritoneal findings.
3. Determine the presence of symptoms/signs suggestive of immediate need for operative intervention:
 - a. Herniated abdominal contents.
 - b. Massive bleeding from the wound.
 - c. Obvious peritoneal signs consistent with hollow viscous injury or hemoperitoneum.
 - d. Signs of hemodynamic instability associated with the abdominal injury.
 - e. Signs of lower extremity ischemia suggestive of vascular injury.
 - f. All gunshot wounds with path or other evidence of intraperitoneal penetration or

- retroperitoneal organ injury.
- g. Blood per NG/OG tube, rectum, Foley.
- 4. If any of the above signs are present, then take patient to the operating room immediately for exploratory laparotomy.
- 5. For stab wounds, if none of the above signs are present, determine the location of the wound and classify as:
 - a. Anterior.
 - b. Thoracoabdominal.
 - c. Posterior or flank.
- 6. If the stab wound is anterior:
 - a. Determine if the wound enters the peritoneal cavity by visually exploring the wound. This is done by infiltrating local anesthesia, after which the wound is prepped and draped. The wound is extended if necessary to allow a visual inspection of the wound to determine its depth. The liberal use of retractors and assistants will facilitate adequate wound exploration. Laparoscopy has utility in the evaluation of anterior abdominal stab wounds.
 - b. If the wound does not penetrate the anterior fascia, then the wound can be debrided, irrigated and closed. The patient may be discharged if no other injuries exist.
 - c. If the wound does penetrate the anterior fascia, then laparotomy may be considered. OR If the patient still has no evidence of peritoneal irritation, then a DPL may be performed or the patient may be admitted for observation. Prior to DPL, a Foley catheter and NG/OG tube should be placed. Laparotomy is indicated with gross hematuria or blood from NG/OG tube. The threshold for a DPL in these circumstances is an RBC of 5000/mm³. Lavage fluid from the Foley catheter, NG tube or chest tube also mandates exploration. If the DPL is benign, the patient will be admitted for observation.
- 7. If the wound is thoracoabdominal:
 - a. Obtain chest X-ray with wound markers to determine the presence of chest injury and to determine the relationship of the entry wound to the diaphragm.
 - b. If wound could possibly have penetrated the diaphragm, consider:
 - i. Exploratory laparotomy.
 - ii. DPL with threshold for the RBC count of 5000/mm³.
 - iii. Diagnostic laparoscopy. If laparoscopy is performed, be prepared to insert a chest tube, as the insufflation gas may cause a tension pneumothorax through a hole in the diaphragm.
 - iv. Thoracoscopy to inspect the diaphragm.
- 8. If the wound is posterior or flank:
 - a. Insert Foley catheter to determine the presence of hematuria.
 - b. Obtain a triple-contrast CT scan to determine injury by retroperitoneal organs.
 - c. The CT scan can often detect the path of injury.
 - d. OR Admit patient for close observation if low probability of injury.
- 9. For pelvic wounds that may have traversed the rectum:
 - a. Perform anoscopy and sigmoidoscopy to determine the presence of a mucosal defect.
 - b. Consider diversion, drainage, and rectal washout if injury is found.

10. For all patients taken to OR for exploratory laparotomy:
 - a. Once the decision to go the OR is made, don't delay!!!!
 - b. Assure blood availability for OR.
 - c. Administer prophylactic antibiotics for bowel flora (www.east.org).
 - d. Prep widely.
 - e. Obtain a rapid one-shot IVP to determine the presence of bilateral kidneys if hematuria is present. Often this can be performed in the OR to avoid delay in initiating the laparotomy.

PRACTICE GUIDELINES: NON-OPERATIVE MANAGEMENT OF SPLENIC INJURIES

Refer to www.east.org "Practice Management Guidelines for the Non-operative Management of Blunt Injury to the Liver and Spleen"

OBJECTIVES:

1. To define situations in which non-operative management of splenic injuries is safe.
2. To define a clinical pathway for the non-operative management of splenic injuries.

DEFINITIONS: Grading of Splenic Injury: AAST Spleen Injury Scale 1994

Grade of Injury	Anatomic Findings
Grade I	Subscapular hematoma: <10% surface area Capsular tear: <1 cm in depth
Grade II	Subscapular hematoma: nonexpanding, 10-50% surface area Intraparenchymal hematoma: nonexpanding, <5 cm in diameter Capsular tear: active bleeding, 1-3 cm, does not involve trabecular vessel
Grade III	Subscapular hematoma: >50% surface area or expanding Intraparenchymal hematoma: >5 cm or expanding Laceration: >3 cm in depth or involving trabecular vessels
Grade IV	Intraparenchymal hematoma: ruptured with active bleeding Laceration: involving segmental or hilar vessels producing major devascularization (>25% of spleen)
Grade V	Shattered spleen Hilar vascular injury that devascularizes spleen

GUIDELINES:

1. Indications: Non-operative management of splenic injury can be considered when all of the following conditions have been met:
 - a. Diagnosis of splenic injury on CT scan.
 - b. Hemodynamically normal patient that has not required or has responded quickly to the resuscitation.
 - c. No other major intra-abdominal injury requiring operative intervention

- d. Available for monitoring.
 - e. No premorbid illnesses that suggest the patient could not tolerate blood loss (e.g., severe ischemic heart disease).
 - f. Immediate availability of operating room 24 hours a day
 - g. Blood bank with capability of immediate transfusion
 - h. An Intensive Care Unit for close monitoring
2. Protocol (Every patient with a splenic injury might not require everyone of the following steps. Therapy should be tailored to the patient's needs.):
- a. Admit to Step Down or Intensive Care Unit.
 - i. Monitor hourly vital signs.
 - ii. Bed rest.
 - iii. NPO.
 - iv. Draw serial hematocrit and hemoglobin every 6 hours until stable
 - b. When hematocrit is stable and there have been no adverse hemodynamic events:
 - i. Transfer to regular floor or discontinue telemetry.
 - ii. Advance diet.
 - iii. Hematocrit and hemoglobin daily.
 - iv. Bed rest until stable. There is no evidence based literature for the duration of bed rest
 - v. If stable and tolerating a diet, discharge 2 days after ambulation begins or as condition allows.
 - c. After discharge:
 - i. No major contact sports (e.g., football) for approximately 3 months. Instruct to return to ED if developing worsening left upper quadrant pain, dizziness, syncope or hypotension.
 - ii. Office follow up based on clinical condition. Follow up CT scan can be used to document healing prior to release to work, contact sports, etc. Routine follow up CT scanning in asymptomatic patients is not supported in the literature.
3. If splenectomy is required, administer vaccines before discharge:
- a. Pneumococcus vaccine (Pneumovax).
 - b. Meningococcus vaccine.
 - c. Haemophilus influenzae vaccine.

NOTE: Angiographic embolization is an adjunct to the non-operative management of hemodynamically stable patients with splenic (and hepatic) injury and on going hemorrhage, i.e., contrast blush on CT scan.

PRACTICE GUIDELINES: MANAGEMENT OF LIVER INJURIES

Refer to www.east.org "Practice Management Guidelines for the Non-operative Management of Blunt Injury to the Liver and Spleen"

OBJECTIVES:

1. To define situations in which non-operative management of liver injuries is safe.

2. To outline a protocol for non-operative management of liver injuries.
3. To outline a protocol for the operative management of liver injuries.

DEFINITIONS:

Grading of Fractures of the Liver: AAST Liver Injury Scale 1994

Grade of Injury	Anatomic Findings
Grade I	Subcapsular hematoma: 10 cm surface area Capsular avulsion, parenchymal fracture <1 cm deep
Grade II	Subcapsular hematoma: 10-50% surface area Intraparenchymal hematoma: nonexpanding, < 10 cm Parenchymal fracture: 1-3 cm depth, < 10 cm length
Grade III	Subcapsular hematoma: >50% surface area or expanding Intraparenchymal hematoma: > 10cm or expanding or ruptured with bleeding Parenchymal fracture: >3 cm depth
Grade IV	Parenchymal disruption of 25-75% of hepatic lobe
Grade V	Retrohepatic vena cava and/or hepatic vein injury Parenchymal disruption > 75% of hepatic lobe
Grade VI	Hepatic avulsion

GUIDELINES:

1. Indications for operative and non-operative management of liver injuries:
 - a. Operative management of liver injuries should be considered when there is ongoing bleeding from the liver injury resulting in unstable vital signs or there is the possibility of other injuries.
 - b. **NOTE:** Angiographic embolization is an adjunct to the operative and non-operative management of patients with hepatic injury, on going hemorrhage, i.e., contrast blush on CT scan, inability to control hemorrhage at surgery, etc..
 - c. Non-operative management of liver injuries can be undertaken in the otherwise stable patient.
2. Non-operative management:
 - a. Admit to Step Down or Intensive Care Unit.
 - i. Monitor hourly vital signs until normal.
 - ii. Bed rest.
 - iii. NPO.
 - iv. Draw serial hematocrit and hemoglobin every 6-8 hours until stable.
 - b. When hematocrit is stable and there have been no adverse hemodynamic events:
 - i. Transfer to regular floor.
 - ii. Advance diet.

- iii. Hematocrit and hemoglobin daily.
- iv. Bed rest 2 days. Grade I and II liver fractures may ambulate immediately.
- v. If stable and tolerating diet may be discharged as condition allows.

There are no evidence-based recommendations for days of bedrest, days of hospitalization or days of restricted activity after non-operative management of hepatic injury. Healing and recovery are dependent upon the severity of the liver injury and the patient's own physiology.

- c. After discharge:
 - i. Return to work or school as clinical condition warrants.
 - ii. No major contact sports for 3 months.
 - iii. Return to clinic as clinical condition warrants.
 - iv. Follow up CT scan of liver may be utilized to document healing prior to return to work or contact sports. Remember that evidence of radiologic healing may or may not be the same as physiologic healing.
 - v. Routine follow up CT scanning in the asymptomatic patient does not seem to be supported in the literature.
 - vi. Instruct to return to the ED if:
 - (1) Worsening RUQ pain.
 - (2) Fever.
 - (3) Jaundice.
 - (4) Dizziness, increasing abdominal pain.
 - (5) Bloody stool or UGI bleeding (hemobilia).
- 3. Complications of hepatic trauma:
 - a. Fever and/or jaundice – consider biloma.
 - i. CT scan to confirm.
 - ii. Percutaneous drainage.
 - iii. Consider ERCP with stent placement and/or sphincterotomy.
 - b. UGI bleed two to four weeks after injury – consider hemobilia.
 - i. CT scan to confirm large intrahepatic injury or clot.
 - ii. Angiography to confirm etiology.
 - iii. Angiographic embolization of vessel.
 - iv. Do not explore for hemobilia.
 - c. Hypotension, drop in hematocrit seven to ten days after non-operative management of severe liver injury:
 - i. Repeat bleed, usually arterial.
 - ii. Admit to ICU if stabilized or if not.
 - iii. Angiography to confirm etiology if not proceeding to OR.
 - iv. Angiographic embolization of the vessel.

NOTE: Angiographic embolization is an adjunct to the non-operative and operative management of hemodynamically relatively stable patients with hepatic injury and on going hemorrhage, i.e., contrast blush on CT scan, inability to control hemorrhage at surgery, delayed hemorrhage, pseudoaneurysm formation, etc.

PRACTICE GUIDELINES: DAMAGE CONTROL

OBJECTIVE:

Define the technique and expectations of "damage control" used in the operating room to temporarily control life-threatening injuries. Define the situations in which "damage control" should be helpful in stabilizing patients.

DEFINITION:

Damage Control: This is a three phase technique. The first phase of Damage Control is the operative phase where the only priorities are controlling hemorrhage with all techniques available and limiting contamination from hollow viscus injury. Definitive repair of bowel or visceral injuries is not attempted and temporary wound closure is used. The second phase of Damage Control is continued resuscitation in the ICU. (correction of hypothermia, acidosis and coagulopathy.) The third phase of Damage Control is(are) return(s) to the OR after the patient has stabilized. Completion of repairs, searching for missed injuries and wound closure is accomplished.

GUIDELINES:

1. The patient with severe abdominal or retroperitoneal injuries with suspected bleeding is brought to the OR immediately.
2. Inform the anesthesiologist of the severity of the injuries so that appropriate intravenous access can be obtained if not already done. Two large bore intravenous lines (preferably introducers) are essential.
3. Assure that blood salvage techniques are available.
 - a. Make sure that the Blood Bank is aware of the need for large volume transfusions and component therapy.
 - b. Provide hypothermia protection.
 - i. Warm the room > 85°.
 - ii. Bair Hugger.
 - iii. Warm IV fluids and blood products.
 - iv. Wrap the patient's head to prevent heat loss
4. Open the abdomen and assess the injuries, pack all four quadrants and examine for mesenteric bleeding. **Control bleeding first!** Packing may be the safest way to control hemorrhage in coagulopathic, acidotic patients. Consider damage control in the following situation:
 - a. Preexisting or rapidly developing hypothermia, coagulopathy, acidosis.
 - b. Non-surgical brisk bleeding
 - c. Diffuse uncontrollable retroperitoneal or pelvic bleeding.
 - d. Severe fracture of the liver that cannot be controlled with ligation, suture or clips.
 - e. Massive bleeding from multiple sources in which it appears that definitive care of all injuries may lead to prolonged operative time or additional bleeding which could lead to hypothermia or coagulopathy.
5. Technique of damage control:
 - a. Remove the packs from areas of likely bleeding first.
 - b. Control all surgical bleeding as rapidly as possible. Do splenectomy rather than splenorrhaphy, nephrectomy rather than renorrhaphy. Pack areas of oozing: liver,

- retroperitoneum, pelvis, and mesentery.
- c. Consider liberal use of fibrin glue, Avitene Sheets, etc on raw, bleeding surfaces. Once the bleeding is controlled as much as possible, examine for hollow viscus injuries (see #6 below).
 - d. Once the decision for damage control has been made, proceed rapidly. **The goal of this procedure is to stop the bleeding and get the patient to the ICU where the clotting factors may be replaced and physiologic disturbances such as acidosis, hypoxemia and ischemia may be definitively corrected.**
6. Management of intestinal injuries:
 - a. Small holes: whip stitch with a running or interrupted suture. Do not attempt definitive repair.
 - b. Large defects or devitalized areas: resect the affected area with GIA stapler. Do not attempt to reanastomose. Do not create ostomies. Assess bleeding.
 7. If controlled with packing, either leave the packs in place or re-pack the area with laparotomy sponges or moist towels. Consider using a Vi-drape (two of them stuck together to avoid the adhesive edge) over the surface of the liver to facilitate pack removal.
 8. Close abdomen with any of the accepted temporary closure techniques.
 - a. Temporary closure using vacuum pack technique
 - b. Avoid closure resulting in Abdominal Compartment Syndrome or damaging fascia.
 9. Return to the ICU rapidly to improve cardiac output, acidosis, hypothermia, and coagulopathy.
 - a. Consider PA catheter or other device to monitor cardiac output in these patients.
 - b. Antibiotics.
 - c. Measure intra-abdominal pressure (this may not be necessary depending on the closure technique used) through Foley as necessary.
 - i. If >30 cm H₂O and decreasing urine output, inability to ventilate or decreasing BP, consider loosening the abdominal closure.
 - ii. Return to the OR for definite procedure and fascial closure when:
 - (1) a. Normothermic.
 - (2) Coagulopathy resolved.
 - (3) Hemodynamics are stabilized.
 - (4) Intra-abdominal sepsis related to duration of packing remaining in place.

PRACTICE GUIDELINES: DETECTION OF INTRA-ABDOMINAL HYPERTENSION
OBJECTIVE:

To define the method of measuring intra-abdominal pressure to detect those patients at risk for abdominal compartment syndrome.

DEFINITION: Increased intraabdominal pressure can result in compression of the inferior vena cava compromising venous return to the heart and subsequently cardiac output. Compression of mesenteric venous flow is noted with IAPs as low as 20 cm H₂O.

Intraabdominal pressure is determined by using pressure measurement taken in the urinary

bladder.

EQUIPMENT

Sterile gloves	Betadine swabs
Saline	.9 NS (500cc for transduced line)
Transducer set or manometer	16-18g needle
60cc syringe	Hemostat or Kelly clamp

PROCEDURE

1. Assemble single line transducer kit with 500cc bag .9NS and free any entrapped air. Attach a 16 or 18 gauge needle to the end of the transducer line.
2. Prep "sample port" on Foley catheter with Betadine.
3. Clamp Foley catheter just distal to the "sampling port".
4. Inject 50-100cc .9NS via the "sampling port" into the Foley catheter.
5. The clamp is released just enough to allow the tubing proximal to the clamp to fill with fluid from the bladder eliminating any air in that section of tubing. The clamp is then reapplied.
6. Attach the transducer set to the sampling port on the Foley. If a manometer is used instead of a transducer it is attached in a similar fashion after all tubing and the manometer has been fluid filled.
7. Level the transducer to the level of the symphysis pubis and zero. If a manometer is used, the zero level is the pubic symphysis.
8. Record bladder pressures.

The threshold for abdominal decompression is in continual evolution. Recent studies have advocated decompression in the face of IAP of 20-25 mmHg associated with evidence of organ dysfunction. IAP above 35 mmHg almost always dictate decompression even in the absence of organ dysfunction.

PRACTICE GUIDELINES: PELVIC FRACTURES

OBJECTIVES:

1. To prevent life-threatening hemorrhage.
2. To establish early pelvic stability to decrease pain and allow an upright chest posture in order to minimize pulmonary complications.
3. To diagnose and manage concomitant urologic injuries.

DEFINITIONS:

Unstable pelvis: An unstable pelvis ring disruption may be rotationally and/or vertically unstable.

Open pelvic fracture: Implies a soft tissue injury allowing potential contamination of the fracture and markedly increased mortality rate. Types of soft tissue injuries include perineal lacerations, vaginal tears and rectal tears.

GUIDELINES:

1. Follow the ABC's.
2. Examine and document distal neurovascular status of limbs.
3. Examine for urethral blood, scrotal or perineal hematoma, high riding prostate.
 - a. If present, obtain urethrogram prior to Foley.
 - b. If hematuria present, obtain cystogram.
4. Examine for perineal, vaginal or rectal lacerations.
5. **Avoid excessive movement** (this includes repetitive stress exams of the pelvis). Every time the fracture moves, there is more blood loss. A sheet placed tightly around the pelvis will stabilize the fracture and reduce intrapelvic volume.
6. Obtain pelvic X-ray (do not delay transfer).
7. If patient is hemodynamically unstable:
 - a. Continue vigorous fluid resuscitation. Consider maintaining BP 80 –90 mmHg until hemorrhage controlled.
 - b. Tightly wrap pelvis with sheet.
 - c. Make transfer arrangements immediately.
 - d. Avoid coagulopathy and hypothermia.

THE FOLLOWING ARE INTERVENTIONS FOR DEFINITIVE CARE A MULTIDISCIPLINARY TEAM APPROACH IS MANDATORY

8. Perform DPL above umbilicus.
 - a. If grossly positive (>10 ml blood), perform laparotomy.
 - b. Orthopedics to place pelvic fixator as early as possible if appropriate to fracture type. External fixator application prior to laparotomy should be accomplished if at all possible. Tightly wrapped sheet will serve well.
 - c. If DPL is grossly negative, Orthopedics to place pelvic fixator if appropriate to fracture type.
9. If remains hemodynamically unstable despite adequate fluid resuscitation and has an unstable pelvic fracture, perform angiography.
 - a. If obvious bleeding, perform angiographic embolization.
 - b. If no obvious bleeding, search for other sources.
10. Provide adequate clotting factors (i.e., FFP, platelets, cryoprecipitate) as needed.
11. If DPL is positive by cell count, place external fixator (sheet) and obtain pelvic angiogram prior to laparotomy.
12. If urethrogram shows urethral disruption, place suprapubic catheter placement.
13. If patient has major perineal laceration, go to OR. OR should be undertaken after angiography if possible. If not, a Damage Control approach should be accomplished followed by angiography if the patient remains unstable.
 - a. Control bleeding.
 - b. Double-barrel sigmoid colostomy.
 - c. Distal segment washout.
 - d. Debride and pack wound. Closure may be possible on a delayed basis.

PRACTICE GUIDELINES: OPEN FRACTURE

OBJECTIVES:

1. To minimize the development of infection and ultimate osteomyelitis. To define the types of open fractures and prioritize injury management based on them.
2. See also www.east.org "Prophylactic Antibiotics in Open Fractures", "Optimal Timing of Long Bone Fracture Stabilization in Polytrauma Patients" and "Management of Penetrating Trauma to the Lower Extremity"

DEFINITIONS:

Grade I	Skin opening of 1 cm or less, quite clean. Low velocity mechanism of injury. Minimal muscle contusion. Simple transverse or short oblique fractures.
Grade II	Laceration more than 1 cm long, with extensive soft tissue damage, flaps or oblique fractures with minimal comminution.
Grade III	Extensive soft tissue damage including muscles, skin, and neurovascular structures. Often a high-velocity injury with a severe crushing component.
Grade IIIA	Extensive soft tissue laceration, adequate bone coverage. Segmental fractures, gunshot injuries.
Grade IIIB	Extensive soft tissue injury with periosteal stripping and bone exposure. Usually associated with massive contamination.
Grade IIIC	Vascular injury requiring repair

GUIDELINES:

1. Follow ABC's. Extremity fractures assume low priority in the multiply injured patient unless there is significant bleeding or impending loss of skin integrity by dislocation or displaced fracture.
2. When patient is stable, examine the fracture and document distal neurovascular status of limb.
3. Remove all gross contamination using sterile saline and cover all wounds with sterile dressing soaked in saline only.
4. Grossly align limb or reduce dislocation.
 - a. Splint femur fractures with Hare traction or similar splint.
 - b. Splint other fractures with aluminum or plaster splints, including joint above and below the fracture.
 - c. Exposed, angulated bone should be pulled below the skin during reduction as much as possible.
5. Radiographs in two planes, including joints above and below fracture. If the patient is to be transferred to the Trauma Center, extremity radiographs are not necessary prior to transfer if the transfer will be delayed obtaining those films.
6. Prophylactic antibiotics.
 - a. Ancef 1 gm every 8 hours.
 - b. For Grade III fractures additional coverage for gram negative organisms
 - c. If there is fecal/Clostridial contamination add penicillin G 4-5 million units every 4

hours.

7. Tetanus prophylaxis as indicated.
8. Consult orthopedics.
 - a. Surgical irrigation and debridement with definitive stabilization within 6 hours of injury.

PRACTICE GUIDELINES: MANAGEMENT OF PENETRATING NECK INJURY

OBJECTIVE: To provide guidelines for the management of a penetrating injury to the neck, specifically as it relates to the need for operative exploration and the ordering of diagnostic studies.

DEFINITIONS: Penetrating Injury: Any inflicted injury that penetrates the skin. These guidelines do not apply to penetration of the oral or pharyngeal mucosa as might be seen with medical instrumentation, etc.

GUIDELINES (Thompson EC, Porter JM, Fernandez LG. Penetrating neck trauma: an overview of management. J Oral Maxillofac Surg. 2002;60:918–923.):

1. For all penetrating injuries of the neck, first apply all of the principals of ATLS (see "Prioritization Guidelines") and Pay particular attention to airway, since this will be the most life-threatening associated condition. Emergency cricothyrotomy should be avoided in the Emergency Department, if possible, as a contained hematoma can be released with disastrous consequences.
2. Penetrating neck injuries frequently involve the thorax.
3. The following are consistent with significant cervical injuries:
 - a. Shock.
 - b. Active hemorrhage.
 - c. Expanding hematoma.
 - d. Need for surgical airway.
 - e. Air bubbling from the wound.
 - f. Stridor.
 - g. Retropharyngeal air
 - h. Dysphonia
 - i. Carotid bruit
 - j. Neurologic deficit
4. Diagnostic Modalities Available for Non-Operative Evaluation of Neck Wounds
 - a. Oropharyngeal Examination
 - b. Arteriography
 - c. Ultrasonography
 - d. Bronchoscopy
 - e. Esophagoscopy
 - f. Barium/Gastrografin swallow
 - g. CT/CTA/MRA
5. A determination should be made as to whether the platysma has been penetrated. Slash wounds can easily be examined to determine this. For puncture wounds that seem superficial,

the wound can be anesthetized and enlarged for a direct visual observation to determine if the platysma is intact. DO NOT PROBE NECK WOUNDS!! If the platysma is intact, then close the wound if possible and discharge.

6. If the platysma has been violated, then classify the wound as:
 - a. Zone I – below cricoid cartilage.
 - b. Zone II – between cricoid and angle of the mandible.
 - c. Zone III – above the angle of the mandible.
7. Obtain a CT of the neck and chest with IV contrast.
8. Zone I injuries:
 - a. Stable Patient with clinical signs of injury:
 - i. Selective Management with some/all/none of the modalities listed in #4 depending upon patient status.
 - ii. If positive findings – surgical repair
 - iii. If negative findings - observation
 - iv. Unstable patient who is not responding to resuscitation must go to the OR for immediate exploration
9. Zone II injury - use clinical findings to classify as low or high probability of vascular and/or aerodigestive injury.
 - a. High probability injuries or unstable patient:
 - i. Take to the operating room for neck exploration.
 - b. Low probability injuries:
 - i. Selective Management with modalities listed in #4.
 - ii. Subsequent treatment based on findings
 - iii. Consider Expectant Management (observation only). See NOTE below.
10. Zone III injuries:
 - a. Unstable patient:
 - i. Surgical exploration or emergent angiography if lesion not surgically correctable, e.g., base of skull.
 - b. Stable patient:
 - i. Selective Management with modalities in #4.
 - c. Treat based on findings.

For penetrating neck injuries that have violated oral mucosa, treat with antibiotics.

NOTE: Zone I and III injuries are difficult to access surgically. CT Angiography is a major diagnostic tool in these areas. Angiography may be needed to control bleeding.

Expectant Management of Zone II injuries with no diagnostic interventions other than observation is being used in some Trauma Centers in patients with no clinical signs of injury. This modality, if employed, should be used with caution and in settings where problems may be immediately identified and resolved.

PRACTICE GUIDELINES: MANAGEMENT OF THE PEDIATRIC PATIENT

OBJECTIVE: To define clinical guidelines for the management of the injured child by the

Trauma Team.

DEFINITION:

Pediatric patient: A child who might have a different response to injury and physiology that may require an altered approach to diagnosis and treatment after major trauma. This will be individualized to the particular patient. It is impossible to identify a pediatric patient by a specific maximum age, since growth and development occur differently in different children

GUIDELINES:

1. Follow the guidelines established by ATLS. Do not allow the age difference in the patient to divert attention away from the ABC's, primary survey, resuscitation, secondary survey and reassessment phase of trauma care.

	Pink 13-16 lbs	Red 17-20 lbs	Purple 21-25 lbs	Yellow 26-31 lbs	White 32-40 lbs	Blue 41-51 lbs	Orange 52-64 lbs	Green 65-85 lbs			
QUICK REFERENCE - EMERGENCY CHART											
ZONE	3 kg	4 kg	5 kg	PINK	RED	PURPLE	YELLOW	WHITE	BLUE	ORANGE	GREEN
ET TUBE (mm)	3.5 uncuffed	3.5 uncuffed	3.5 uncuffed	3.5 uncuffed	3.5 uncuffed	4.0 uncuffed	4.5 uncuffed	5.0 uncuffed	5.5 uncuffed	6.0 cuffed	6.5 cuffed
Lip-Tip (cm)	9-9.5	9.5-10	10-10.5	10-10.5	10.5-11	11-12	12.5-13.5	14-15	15.5-16.5	17-18	18.5-19.5
Suction	8 F	8 F	8 F	8 F	8 F	8-10 F	10 F	10 F	10 F	10 F	12 F
L-Scope blade	1 straight	1 straight	1 straight	1 straight	1 straight	1 straight	2 straight/ curved	2 straight/ curved	2 straight/ curved	2.3 straight/ curved	2.3 straight/ curved
Stylet	6 F	6 F	6 F	6 F	6 F	6 F	6 F	6 F	14 F	14 F	14 F
Oral Airway	50 mm	50 mm	50 mm	50 mm	50 mm	60 mm	60 mm	60 mm	70 mm	80 mm	80 mm
NP Airway	14 F	14 F	14 F	14 F	14 F	18 F	20 F	22 F	24 F	26 F	30 F
BVM <small>Minimum Volume-mLs</small>	450 mL	450 mL	450 mL	450 mL	450 mL	450 mL	450 mL	450-750 mL	750-1000 mL	750-1000 mL	1000 mL
ETCO₂	PEDIATRIC DETECTOR	PEDIATRIC DETECTOR	PEDIATRIC DETECTOR	PEDIATRIC DETECTOR	PEDIATRIC DETECTOR	PEDIATRIC DETECTOR	PEDIATRIC DETECTOR	ADULT DETECTOR	ADULT DETECTOR	ADULT DETECTOR	ADULT DETECTOR
LMA	1	1	1	1.5	1.5	2	2	2	2-2.5	2.5	3
TIDAL VOLUME	24-36 mL	30-50 mL	40-60 mL	50-80 mL	70-100 mL	80-130 mL	100-160 mL	130-200 mL	170-250 mL	210-320 mL	260-400 mL
FREQUENCY (BPM)	20-25	20-25	20-25	20-25	20-25	15-25	15-25	15-25	12-20	12-20	12-20

2. Primary survey and resuscitation:
 - a. Airway:
 - i. Oral airway can be used in the unconscious patient – do not insert it upside down and rotate 180 as is done in an adult.
 - ii. Orotracheal intubation is preferred method of obtaining an airway:
 - (1) Maintain C-spine immobilization.
 - (2) Refer to pediatric equipment chart for proper blade and tube.
 - (3) Use uncuffed ETT tube in tubes < 6 mm internal diameter
 - (4) Position the tube 2-3 cm below the vocal cords.
 - (5) Auscultate both sides of the chest in the axillae.
 - (6) Confirm position with chest X-ray
 - iii. Surgical cricothyrotomy should be avoided if at all possible in the infant or small child.

- b. Breathing:
 - i. Chest tubes are inserted similarly to adults.
 - ii. The size of chest tube can be determined on the Breslow Tape.
 - c. Circulation:
 - i. Rapid evaluation for signs of poor tissue perfusion: tachycardia, delayed capillary refill, mottled skin, cool skin, etc. Decreased blood pressure is a very late finding of shock in the pediatric patient.
 - ii. Intravenous access: Attempt peripheral vein cannulation twice, and if unsuccessful, proceed to other access sites:
 - (1) Infant and child < 6 – intraosseous approach.
 - (2) Child > 4 – femoral vein cannulation.
 - (3) Child > 4 – central venous line via femoral, subclavian or jugular approach.
 - (4) Any child – cutdown:
 - (a) Greater saphenous vein in the ankle.
 - (b) External jugular.
 - (5) Median cephalic vein at the elbow.
 - (6) Femoral vein in the groin
 - iii. Fluid infusion:
 - (1) Initial bolus is 20 mg/kg with warmed LR or NS.
 - (2) If remains unstable, then re-bolus as above.
 - (3) If remains unstable, then administer 10 ml/kg warmed PRBC's.
 - (4) If remains unstable, then consider other forms of shock or the need for emergent operative intervention.
 - d. Disability:
 - i. Avoid at all costs: hypotension, hypoxia, hypocarbia, hypercarbia, hyper- and hypoglycemia, hyperthermia. Aggressively treat seizures.
 - ii. Intubation for GCS 8.
 - iii. Maintain normovolemia with LR or NS solution.
 - e. Exposure: make sure the child is rolled with C-spine precautions to examine for all injuries. Beware of hypothermia.
3. For equipment such as NG tubes, Foley catheters, chest tubes, ETTs, etc., refer to pediatric equipment chart (above) and/or Broselow tape.

PRACTICE GUIDELINES: TREATMENT AND OBSERVATION OF PATIENTS INVOLVED IN TRAUMATIC INCIDENTS DURING PREGNANCY

OBJECTIVES:

To define guidelines to be applied to the initial evaluation of the pregnant patient who has sustained a traumatic injury. To coordinate the activities of the Obstetric Service, the Trauma Service and the Emergency Medicine Service.

GUIDELINES:

1. Follow the ATLS protocols including initial assessment, resuscitation and secondary survey. (See Initial Assessment Protocol.) Remember that the mother's welfare comes first so that all of the initial assessment should be directed to the mother while keeping the fetus' welfare in

- mind. This includes X-rays and CT scanning.
2. Assess for pregnancy and gestational age by one or more of the following:
 - a. History and last menstrual period.
 - b. Beta-HCG.
 - c. Prior or immediate sonogram.
 - d. Discussion with primary care obstetrician.
 - e. Fundal height
 3. If 24 weeks or greater by any indicator, including physical exam, contact Labor and Delivery for external fetal monitor to be brought to the trauma room:
 - a. Non-stress test strip to be reviewed by L&D monitoring nurse.
 - b. Any strip that is worrisome for fetal distress should be reviewed by the primary obstetrician (or resident on-call) and perinatologist.
 4. Keep patient (>20 weeks pregnant) on the left side to take uterine pressure off vena cava.
 5. Obtain standard trauma labs dependent on injuries and Kleihauer Betke test *and* D-dimer.
 6. Determine maternal Rh status. If Rh negative, then: Rhogam 300 mcg for 2nd and 3rd trimester or 50 mcg for 1st trimester.
 7. Obtain ultrasound examination.
 8. If this is major trauma requiring transfer to NTICU or Trauma Care Unit, then: Obtain obstetrics consult.
 - a. Continuous fetal monitoring by L&D nurse for at least 24 hours or longer at the discretion of obstetrics.
 9. If this is minor trauma not requiring transfer to trauma specialty unit, then consider 24 hours of continuous fetal monitoring at the discretion of obstetrics.
 10. If the gestational age is less than 24 weeks, then continuous fetal monitoring is not necessary unless ordered by obstetrics. Fetal heart tones should be recorded for documentation.
 11. Perimortem Cesarean Section should be a consideration in extreme cases involving impending fetal demise or fetal death and undertaken in conjunction with Perinatology to resuscitate the fetus and Obstetrics.

PRACTICE GUIDELINES: MANAGEMENT AND TRIAGE OF SEVERELY BURNED PATIENTS

OBJECTIVES:

1. To provide triage parameters and guidelines for the management of the severely burned patient.
2. To provide guidelines to stabilize thermally injured persons until they may be transferred to a burn unit.
3. To provide information to insure smooth transfer of the patient to the burn unit.

DEFINITIONS:

Severely burned patient:

1. This is a patient with a severe burn injury who should be transferred for specialized care to a burn center. The definitions are derived from the classification of burns and guidelines proposed by the American Burn Association.

- a. Partial and full thickness burns that involve >10% total body surface area (TBSA) in patients < 10 years or > 50 years of age.
- b. Partial or full thickness burns > 20% TBSA in other age groups.
- c. Burns associated with significant fractures or other major injury.
- d. Partial and full thickness burns involving the face, eyes, ears, hands, feet, perineum or that involve the skin over major joints.
- e. High-voltage electrical burns.
- f. Inhalation injury.
- g. Lesser burns in patients with significant pre-existing disease.

GUIDELINES:

1. Assess the ABC's. Do not allow your attention to be diverted by the thermal cutaneous burn. Look for life-threatening injuries first.
 - a. Airway - Assess for upper airway injury caused by the inhalation of hot gases or products of combustion. This will potentially result in rapid upper airway occlusion.
 - i. Stridor.
 - ii. Inability to handle secretions.
 - iii. Inability to speak; hoarseness.
 - iv. Burns about face and mouth.
 - v. Erythema in the pharynx.
 - vi. If there is any question about airway occlusion, intubate the patient using the oral route under direct visualization.
 - vii. Assess for smoke inhalation. This may result in lower airway occlusion or noncardiogenic pulmonary edema:
 - (1) All of the above signs, plus:
 - (2) A history of being burned in an enclosed environment.
 - (3) Carbonaceous sputum.
 - (4) Soot in the airway and around the nose and mouth.
 - (5) Uncontrollable coughing:
 - (a) Obtain chest X-ray. REMEMBER: the initial chest X-ray may be normal with severe smoke inhalation.
 - (b) Consider bronchoscopy, looking for erythema of the airway and soot deposition in the trachea and bronchi.
 - (c) If there is any question about smoke inhalation, intubate the patient and place them on positive pressure ventilation.
 - b. Carbon monoxide poisoning:
 - i. Consider carbon monoxide poisoning with any of the above findings, and
 - ii. Carboxyhemoglobin level >10%:
 - (1) Apply FiO₂ as near to 100% as possible.
 - (2) Consider intubating the patient so that 100% oxygen can be given to the patient.
 - (3) Consider cyanide intoxication in enclosed space fires.
 - c. Breathing:
 - i. Assess breath sounds and obtain a chest X-ray. Treat according to the chest injury

guidelines.

- d. Circulation:
 - i. Assess for shock and treat accordingly. Insert two large bore IV's. These may be placed peripherally or centrally. It is acceptable to place the IV's through eschar if it is the only access site. Administer two liters of warmed normal saline solution.
- e. Disability:
 - i. Assess neurologic status.
- f. Expose:
 - i. Remove all clothing and constricting bands or jewelry. Place patient on clean sheet. Sterile sheets are not required. Do not immerse burn into water or ice. Prevent hypothermia.
2. Obtain blood sample for laboratory. CBC, renal panel, UA, clotting studies, blood alcohol (if necessary). Obtain CXR if not already done. Obtain EKG in patients over 45 or those who are having arrhythmias. Obtain arterial blood gas with carboxyhemoglobin level. Insert Foley catheter and NG/OG tube in patients with >20% TBSA burn. Examine the burn when the patient is otherwise stable.
3. Rule of nines for second- and third-degree burn only. The palm of the patient's hand (without the fingers) is equal to 1% TBSA.
4. Assess depth of burn:
 - a. First degree: erythematous, dry, painful, blanches (e.g., sunburn).
 - b. Second degree (partial thickness): blisters, wet, erythematous, painful, blanches (e.g., blister burn).
 - c. Third degree (full thickness): dry, leathery, gray or brown, painless, does not blanch (e.g., surface of football).
 - d. Only second- and third- degree burns are considered when assessing the size of the burn.
 - e. Calculate the fluid requirements using the Parkland formula: $(4 \text{ ml}) \times (\text{wt in kg}) \times (\% \text{ TBSA burn})$ - given over first 24 hours. One-half given in first 8 hours and the rest given in second 16 hours. **NOTE:** calculate first 8 hours from time of burn, not time of presentation to ED.
 - f. Maintain urine output at 0.5 ml/kg/hr in the adult (1.0 ml/kg/hr in child and 2.0 ml/kg/hr in infant <1 year).
 - g. Assess for constricting eschar:
 - i. Usually on extremity but may be on chest or neck.
 - ii. Release eschar medially and laterally.
 - iii. Do not administer antibiotics unless there is a concomitant injury.
 - iv. Administer intravenous boluses of morphine intravenously as needed for pain. Keep the patient comfortable.
 - v. Transfer
 - vi. Mission Hospitals Trauma Center is not a Burn Center. The Trauma Center operates in concert with the Burn Centers in the state.
 - vii. Burn patients should be taken from the scene directly to a burn center if possible. Mission will accept all burn wounds from the scene, by air or ground, assess and stabilize the patient. If the patient can receive definitive care at this facility, the patient will be admitted to Trauma Surgery and Plastic Surgery. If the patient

- requires Burn Center care, the patient is transferred. The ABA criteria are utilized.
- viii. If a burn patient is evaluated by the Mountain Area Medical Airlift crew, is found to be in need of Burn Center care, is found to be stabilized and for safe transport, the crew should contact the nearest Burn Center for direct transfer from the scene. If this is not practical or safe for the patient, Mission will accept the patient and arrange for subsequent transfer.
 - ix. If a burn patient is seen and stabilized in a Regional Hospital and requires Burn Center care based on ABA criteria, the patient should be transferred directly to the Burn Center. Flight Watch at Mission can assist in those arrangements. If Mountain Area Medical Airlift is transporting the patient and in the crew's opinion the patient can be transferred directly to the Burn Center, after consultation with Medical Control, they may proceed directly to the Burn Center.
 - x. If a burn patient is seen in a Regional Hospital and requires further stabilization, Mission will accept that patient, complete the stabilization and subsequently transfer the patient to the Burn Center.
 - xi. For those Regional Hospitals at the periphery of this region, in proximity to Burn Centers, direct Burn Center transfer may be the most expedient approach.
 - xii. Send the following with the patient:
 - (1) Medical records.
 - (2) Laboratory results.
 - (3) Radiographs if done, preferably sent on CD ROM if possible.

PRACTICE GUIDELINES: DEEP VENOUS THROMBOSIS PROPHYLAXIS

See www.east.org "Practice Management Guidelines for the Management of Venous Thromboembolism in trauma patients" See also Evidence Based recommendations from the American College of Chest Physicians in Chest (CHEST 2008; 133:381S–453S).

OBJECTIVE:

To provide guidelines for deep venous thrombosis prophylaxis in the trauma patient.

GUIDELINES:

1. The following patients should be considered candidates for DVT prophylaxis:
 - a. Patients with traumatic brain injury in coma (GCS <8).
 - b. Patients with spinal cord injury.
 - c. Patients with prior history of DVT or pulmonary embolism.
 - d. Patients with fractures or crush injuries of the pelvis and lower extremities.
 - e. Patients requiring bed rest for >72 hours.
 - f. Patients with hypercoagulable states.
2. Routine assessment for DVT with duplex scanning is not indicated
 - a. In high risk patients, clinicians should have a high risk of suspicion. Duplex scanning should also be performed if DVT is suspected.
3. The following prophylaxis should be considered:
 - a. Mobilization: all patients should be mobilized out of bed as soon as possible and when feasible.
 - b. Low molecular weight heparin: enoxaparin 30 mg SQ every 12 hours (or low molecular weight heparin of choice) and leg compression devices in high-risk patients except when

- contraindicated.
- c. Leg compression devices should be used in all patients for whom anticoagulation is contraindicated:
 - i. Traumatic brain injury (first 2-3 days).
 - ii. Spinal cord injury (first 2-3 days).
 - iii. Bleeding diathesis (until resolved).
 - iv. If leg compression devices cannot be placed on both lower extremities, foot pumps should be applied.
 4. If a venous thrombosis is detected, systemic heparin or therapeutic Lovenox should be implemented unless anticoagulation is contraindicated.
 - a. Vena cava filters are indicated in the following circumstances:
 - i. Recurrent pulmonary embolus (PE) despite full anticoagulation. Proximal DVT and contraindications to full anticoagulation.
 - ii. Progression of femoral clot despite anticoagulation.
 - iii. Large free-floating thrombus in the iliac vein or inferior vena cava.
 - iv. After massive PE in which recurrent emboli would prove fatal.
 - v. High risk patients in whom anticoagulation is contraindicated or frequently interrupted for operative procedures.